

Palaeopathology of human remains from Vardbakh and the Black Fortress I, Armenia

Anahit Khudaverdyan

Institute of Archaeology and Ethnography,
National Academy of Science, Republic of Armenia,
Yerevan, 0025, Charents st.15, Armenia
email: ankhudaverdyan@gmail.com, akhudaverdyan@mail.ru

Abstract: *This paper reviews selected diseases in the Vardbakh and the Black Fortress I skeletal samples from Armenia (1st century BC – 3rd century AD). Forty-two skeletons from these two cemeteries were analysed macroscopically for pathological conditions such as traumatic injuries, congenital anomalies, joint diseases, and dental pathology. Trauma to the skull was common, which suggests a high level of inter-personal violence. Individuals from Black Fortress I were somewhat less prone to the development of osteoarthritis of the long bones than the people buried in the Vardbakh cemetery. There was less evidence of excessive dental wear in Black Fortress I although dental abscesses and antemortem tooth loss were more prevalent. Periodontal disease and antemortem tooth loss of the molars were more common in Vardbakh. There is evidence from Vardbakh suggesting that teeth were used in non-masticatory activities. Single cases of plagiocephaly and artificial cranial modification were also noted.*

Key words: cranial trauma, dental pathology, degenerative joint disease, plagiocephaly, artificial cranial modification

Introduction

The Armenian Highland (also known as the Armenian Upland, Armenian Plateau, or simply as Armenia) is the central and highest of three land-locked plateaus that together form the northern sector of the Middle East (Hewsen 1997). The present Armenian Republic (**Figure 1**) is located in the South Caucasus on the eastern end of the Armenian Plateau. In early history the Armenian highlands were a crossroads linking the worlds of East and West (Martirosyan 1964). Those who dominated the Armenian Plateau were in a position to control these lucrative trade routes, to use the fertile valleys that stretch chiefly on the east-west axis, and to dominate the lowlands to the south. Accordingly, Armenia has been an area of frequent military conflicts and its history determined by external forces (Piotrovsky 1959; Arakelyan 1976).

The ancient period in the history of the Armenian people covers nine centuries from the 6th century BC to the 3rd century AD. In the first half of the 6th century BC, the Armenians fell under the domination of the powerful state of Media, later replaced by Achaemenid Persia. With the decline of the Achaemenid Empire, local state formations emerged in Armenia—they recognized but formally the supremacy of the Seleucid kings. In 189 BC, the Kingdom of Great Armenia came into existence bearing the name of its founder Artashes I (189–160 BC).

This kingdom grew into a powerful and prosperous state under Tigranes the Great (96–55 BC) and his son Artavazdes II (55–34 BC).

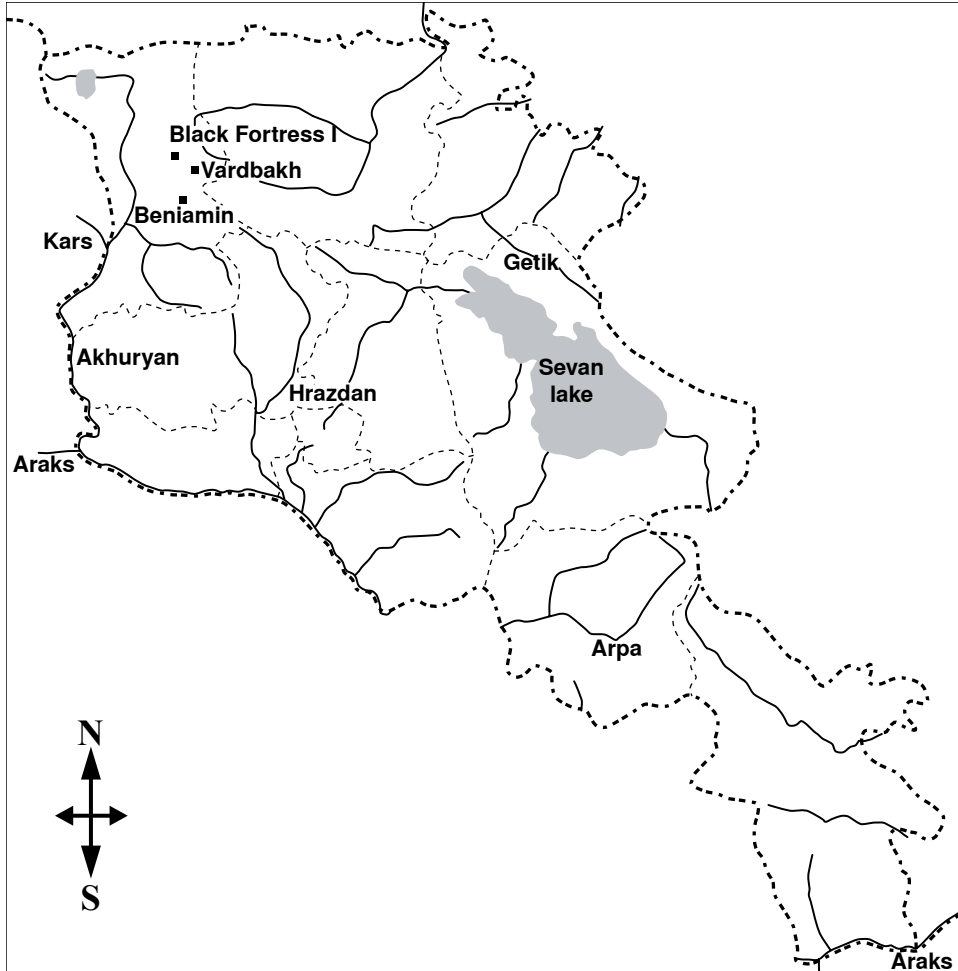


Figure 1. Map of Armenia showing the location of the sites discussed in the paper.

In this period, the process of urbanisation began under Greek influence. The Armenian kings acted as Hellenistic monarchs and patronised the economic life, growth of cities and Hellenistic culture (Arakelyan 1976; Tiratsyan 1988). A polarisation of Armenian social life resulted in a gradual recession of local tribal differences in the provinces and this paved the way for new socially-distinctive features. The cultural divide widened, with the upper social class bent more upon foreign influence as they were in constant touch with either their Iranian or Hellenistic neighbours.

The Kingdom of Great Armenia collapsed at the beginning of the 1st century AD and for a few decades the country became a theatre of war between Romans and Parthians—a war that ended in 63 AD with the defeat of the Roman troops. The Armenian throne was handed

over to Tiridates, the brother of the Parthian king Vologases, and Nero had to crown him as king in Rome. The conflict for control over Armenia lasted for several centuries. The country kept some degree of autonomy under the Sasanian kings who ruled Iran between the 3rd-7th centuries AD (Piotrovsky 1959).

Many anthropological contributions have been made on skeletal populations from Armenia. Most of these, however, concern osteometric studies, especially, cranial studies and odontology (Abdueshvili 1982; Alekseev 1974; Khudaverdyan 2000, 2009a). Very little is known about the health status and epidemiological aspects of historic Armenia, especially in the earliest period (Khudaverdyan 2005) and the present paper provides a contribution that renders this gap somewhat smaller.

Gross observation of abnormal bone changes in ancient skeletons provides the basic direction for palaeopathological diagnosis. The overall health of a population is a function of a number of contributing factors such as systemic stress, infection, and diet (Larsen 1997). For each of these factors, there are specific skeletal indicators that reflect particular aspects of community health.

Diet is reflected in the oral health of a population. A variety of pathological dental conditions provide general insight into diet. In addition, activity patterns and lifestyle can be assessed by studying bone. Because degenerative joint disease (DJD) is influenced by physical activity and biomechanical stress, DJD provides insight into the patterns of activity of a population (Bridges 1992; Jurmain 1999). Also, the study of trauma provides insight into lifestyle and evidence of interpersonal violence in the form of traumatic injuries that reflect the social and physical environment of a population (Lovell 1997). The use of a variety of skeletal indicators may then provide a more thorough understanding of what life was like in ancient Armenia.

Material

The present paper discusses human remains uncovered at Black Fortress I and Vardbakh on the Shiraksky plateau (**Figure 1**) by the archaeological team directed by Stepan Ter-Markaryan. In most cases, integrity of the bones was good. Inhumations in the late ancient period were located in the hillfort or in well-defined burial areas. Individuals were placed in extended positions, accompanied by grave goods including metalwork, pottery, etc. (**Figure 2**).

The Black Fortress site (Sev Amroc in Armenian, near the Aleksandrapol tower in Gyumri) is remarkable due to the archaeological presence of two time periods of ancient Armenian history (Late Bronze Age and 1st century BC – 3rd century AD). The site includes a settlement area as well as a large cemetery referred to as Black Fortress I. It has been excavated since 1993 and the excavations are ongoing (Ter-Markaryan & Avagyan 2000; Avagyan 2003). The fortress was named after the high quality black stone that was available in the region. A total of 28 skeletons were excavated from the site, including 10 males and 13 females. Four children (2–9 years) and one adolescent were the only subadults present in the sample (**Table 1**). Human graves included also some animal remains (Avagyan 2003).

The cemetery in Vardbakh occupied the land of a clergyman. Skeletons were discovered in 73 graves during initial excavations at the site (Ter-Markaryan 1991; Eganyan 2010). Most of the recovered skeletons, however, were re-buried or were lost after excavations. Therefore, human remains from only 14 burials remained available for examination (Khudaverdyan 2005).



Figure 2. Burials from Black Fortress I
(photographs by S. Ter-Markaryan)

The burials contained individuals of both sexes and a range of ages (**Table 1**). In most cases, the upper extremities were placed along the bodies, while in a few cases one or both hands rested on the pelvis. Integrity of the bones were satisfactory. Within the graves, a variety of burial accompaniments were recovered, including jewellery (e.g., rings, pendants), tools (e.g., knives), household goods (e.g., dishes, needles), and other goods (e.g., coins). At the Vardbakh necropolis among the human burials excavators recovered a horse skeleton (Ter-Markaryan 1991). The present author participated in both research projects and took charge of the palaeopathological examination of the skeletal remains from both sites.

Frequencies of observed palaeopathological conditions were compared with another roughly contemporary cemetery in Beniamin, located in the same region of Armenia (Khudaverdyan 2000).

Table 1. Number of individuals from Black Fortress I and Vardbakh.

Age categories	Black Fortress I			Vardbakh		
	male	female	indeterm.	male	female	indeterm.
0–6	-	-	2	-	-	2
7–12	-	-	2	-	-	-
13–20	-	-	1	-	-	-
21–40	6	9	-	3	6	-
41–50	3	4	-	1	2	-
60 +	1	-	-	-	-	-
Total	10	13	5	4	8	2

Methods

Age-at-death and sex were assessed through the use of multiple indicators. Morphological features of the pelvis and cranium were used for the determination of sex (Phenice 1969; Buikstra & Ubelaker 1994:16). A combination of pubic symphysis (Gilbert & McKern 1973; Katz & Suchey 1986; Meindl et al. 1985), auricular surface changes (Lovejoy et al. 1985), degree of epiphyseal union (Buikstra & Ubelaker 1994:16), and cranial suture closure (Meindl et al. 1985) were used for adult age estimation. For subadults, dental development and eruption, long bone length, and the appearance of ossification centres and epiphyseal fusion were used (Moorrees et al. 1963a, 1963b; Ubelaker 1989:60-95; Buikstra & Ubelaker 1994:16).

Several kinds of pathological conditions were scored in the sample of human remains from Black Fortress I and Vardbakh, including trauma, congenital diseases, DJD, dental disease, and artificial cranial deformations. Stress markers, such as enamel hypoplasia, porotic hyperostosis and occupational stress indicators are discussed in detail elsewhere (Khudaverdyan 2010).

In the literature, the terms fracture, injury, and trauma are often used inter-changeably, and the discussion of trauma or injuries may include the grouping of sharp-force weapon injuries and blunt-force trauma. This arises from the numerous definitions of trauma in the palaeopathological and forensic literature (Roberts 1991; Byers 2002). In this paper, the term trauma is only used in the discussion of fractures caused by blunt force trauma as defined by Byers (2002:266). A very important step in trauma analysis is determining when an injury occurred in relation to the death of the individual, i.e. whether it was an antemortem or perimortem injury (Nafté 2000); the distinction between them is based on the presence of any signs of healing (Sauer 1998). The healing stages were recorded based on the system devised by Galloway (1999). Cranial trauma is a likely sign of violence and is more often seen in males than in females, and occurs more often on the frontal and parietal bones (Merbs 1983; Filer 1997; Khudaverdyan 2000, 2005).

Osteoarthritis (OA) of the joints is commonly observed in skeletal collections. Inflammation is uncommon in osteoarthritis, although it can occur with the destructive form. Non-inflammatory osteoarthritis is usually classified into two categories, i.e., primary and secondary osteoarthritis. Primary osteoarthritis is basically due to aging with degeneration of the articular cartilage. In particular, long-standing biomechanical stress is most apparent at the

articular surface of joints as degenerative joint disease (DJD). Secondary osteoarthritis, on the contrary, results from trauma, infection, and/or metabolic disease (Ortner 2003). This form of DJD may occur not only in the major joints of the long bones such as the hip, knee, and shoulder, but in small joints in other areas of the body.

The grading of osteoarthritis was based on the four grade standard developed by P. Sager (1969). Grade 0 indicates a normal bone surface with no osteophytes (“lipping”) around the edges of the articular surface. Grade I is characterised by intermittent osteophytes, or very light new bone growth. Grade II indicates that osteophytes are continuous and exhibit some porotic changes. Grade III arthritis consists of heavy osteophytic lipping, extensive porosity, and possible eburnation. DJD was described by location for each element and joint affected. Each incidence was scored in terms of its manifestation: the collapse of articular cartilage, reactive bone formation (sclerosis), and new growth of cartilage and bone at the joint margins (osteophytes).

Many dental diseases are the result of the diet of an individual. Other defects can be the result of childhood stress or infections (Goodman et al. 1984; Mays 1998). Oral health in the studied skeletal samples was assessed by using six indicators, namely antemortem tooth loss, dental abscesses, periodontal disease, tooth wear, dental caries and dental calculus.

Antemortem tooth loss (AMTL) is characterised by remodelling of the alveolar bone that leads to the obliteration of the tooth sockets. Determining the etiology of AMTL is difficult as evidence may have been lost, especially in instances of carious teeth (Hartnady & Rose 1991). However, the close association between periodontal disease, dental caries, and AMTL is well established, especially in archaeological populations (Larsen 1997). The prevalence of AMTL contributes to the overall picture of oral health in a population. AMTL was assessed based on evidence of resorption of alveolar bone around a tooth socket. If remodelling was evident, and the socket was partially (>2mm) or fully filled in, then a tooth was considered to have been lost antemortem. Sockets that were open and smooth, with no evidence of remodelling, were recorded as having lost teeth postmortem (Turner et al. 1991).

Dental abscesses lead frequently to tooth exfoliation and cause a remodelling process that usually destroys the alveolus and reduces the size of the alveolar process at the site of the tooth loss (Ortner 2003). Abscesses can be caused by various factors, such as pulp necrosis, periodontal infection and trauma. Periapical abscesses can be fatal if the resulting infection spreads into the sinuses (Williams et al. 1983). Although periapical abscesses can occur on the roots of every tooth, Herrera et al. (2000:389-390) found that molars are most frequently affected. In the present study, abscesses were recorded if any trace of infection occurred in the alveolus around the tooth root.

There are four main types of periodontal disease: prepubertal, pubertal, rapidly progressive, and the most common adult periodontitis (Hildebolt & Molnar 1991). Periodontal disease is characterised by horizontal or vertical resorption of alveolar bone due to an extension of bacterially-driven gingival inflammation (Clarke 1990; Hildebolt & Molnar 1991). Horizontal loss is a simultaneous to loss in height of all bone around the tooth roots. Vertical loss is localised around an individual tooth or teeth, forming a defect surrounded by normal alveolar bone (Hillson 1996). Periodontal disease was assessed by measuring the amount of alveolar bone loss. Measurements were taken from the cemento-enamel junction to the surface of the alveolar bone. Only those measurements that exceeded 2mm were recorded as evidence of periodontal disease (Turner et al. 1991).

Dental wear of the functional chewing surface depends on the hardness of food consumed and on whether the teeth are used as tools. Abrasion reflects the physical content of the diet and, for example, has been shown to differ between mobile hunters/gatherers and early farmers (Smith 1972, 1989). Methods of grinding flour (using querns and mortars) result in the inclusion of silica from stalks and husks as well as grit from the mortars and querns into the flour. This, like ash or dirt adhering to baked foods, adds abrasives to the food ingested and can lead to severe abrasion of the teeth (Smith et al. 1984; Smith & Kolska-Horwitz 1998). Molar dental wear was recorded using Scott's scale (1979), while incisor, canine, and premolar wear was scored after Smith (1984).

Dental caries is the demineralisation and dissolution of dental tissues caused by an acid-producing bacterium *Streptococcus mutans* (Goodman & Martin 1993). A number of factors affect the development of the disease, but a diet rich in fermentable carbohydrates has been shown to be cariogenic (Hillson 2008). The disease is manifested in different stages from small enamel opacity to extensive cavity formation on crowns and roots that may result in tooth loss. Carious lesions were examined macroscopically and recorded by tooth type and location. Carious lesions were recorded based on the system devised by Buikstra and Ubelaker (1994:55). Destruction of enamel and irregular margins were the main criteria for identifying lesions. Lesions were recorded on all observable permanent teeth. Care was exercised to avoid confusing carious lesions with pulp exposure due to severe wear.

Dental calculus is mineralised plaque that has accumulated on the enamel surfaces of teeth as the result of poor hygiene and diet (Hillson 1996). There is no satisfactory etiology of this disease, although it is significantly reduced in living populations by attentive oral hygiene (Mandel 1995). Plaque buildup can occur in diets with heavy carbohydrate consumption (Hillson 1996), although protein may increase oral alkalinity, thereby promoting calculus mineralisation. Calculus was recorded on an individual tooth level stating the location and severity of the formation. The location was recorded as supra- or sub-gingival based on the location of the deposit (on the crown or the root) and on the characteristics of the calculus (Hillson 1996). The severity was recorded as slight, medium or considerable deposition following Brothwell (1981:155).

Results and discussion

Trauma

Traumatic injuries are frequently encountered in skeletal populations from Armenia (see Khudaverdyan 2005, 2009a, 2010). In total, in Black Fortress I, 4/23 individuals displayed evidence of antemortem blunt force trauma of the cranium. In Vardbakh, 2/12 adults (both females) suffered from antemortem blunt force trauma of the cranium.

Traumatic injury of the nasal bones was observed in three females from the Black Fortress I cemetery (burials 9, 15, 1/26), possible evidence of domestic violence (Walker 1997). Also, one adult male skull from Black Fortress I (burial 4) showed a remarkable healed fracture of the nasal bones; the nasal septum had shifted (**Figures 3 & 4**). The nose was considerably deformed and the displacement of bone fragments was apparent.

Of the 35 adults in the Black Fortress I and Vardbakh skeletal populations, six individuals suffered traumatic injuries. All of these individuals presented evidence of cranial trauma,

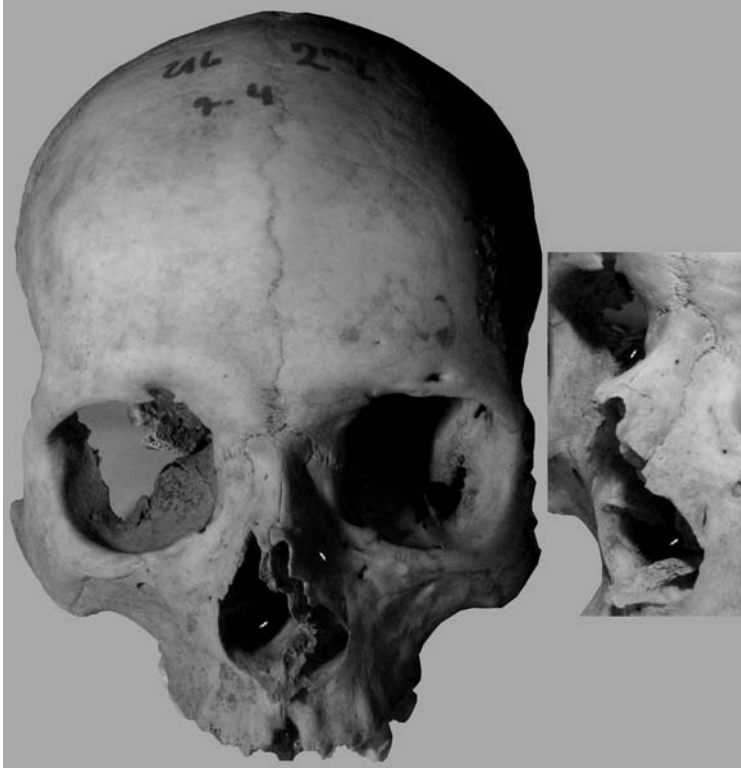


Figure 3. Fracture of the nasal bones with septum displacement. Black Fortress I, burial 4/1.

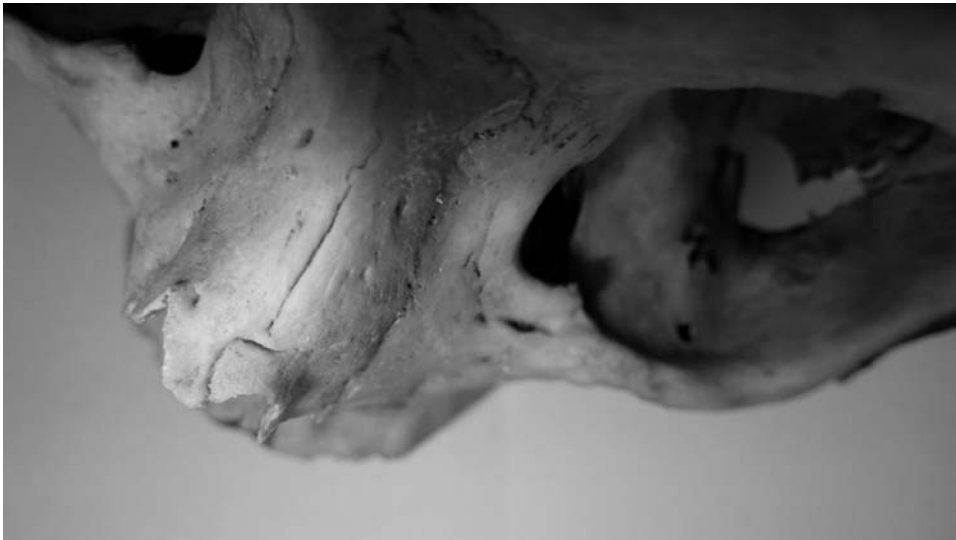

Figure 4. Fracture of the nasal bones, detail. Black Fortress I, burial 4/1.

which may be related to inter-personal violence. This observation is consistent with the historical sources which report almost constant military conflicts and general social instability in the region, related to its position between Roman and Parthian/Sasanian states. There was less evidence of traumatic events in the Beniamin (1st century BC – 3rd century AD) skeletal material. Of the ninety-one adults (62 females, 29 males) in the Beniamin skeletal population, six suffered from antemortem cranial trauma, among them three females and three males (Khudaverdyan 2000, 2010).

A case of plagiocephaly

Plagiocephaly, which refers to a cranial deformation, can be divided into several types. Synostotic plagiocephaly, also known as craniosynostosis, is caused by the premature fusion of one or more cranial sutures of the skull, causing the head to grow into an unusual shape. It carries the risk of intracranial hypertension, although this occurs in less than 10% of modern cases when only a single suture is involved (Gault et al. 1992). The etiology of plagiocephaly is likely multifactorial, including genetic and epigenetic factors (Cohen & MacLean 2000; Kabbani & Raghuvver 2004).

Craniosynostosis was observed in a cranium from Vardbakh (burial 5/2, **Figure 5**). Most cases of craniosynostosis, both of genetic or epigenetic in origin, are normally present before birth, and become more evident during the first year of life. Both the cognitive capabilities and the aesthetics of an individual are affected (Cohen & MacLean 2000).

The cranium may be deformed not only due to congenital condition, but also due to intentional manipulation during the lifetime of an individual or as a result of postmortem factors in the burial (e.g., pressure) (Ortner 2003). For that reason, careful examination of the deformation pattern is necessary. Cranium 5/2 from Vardbakh displays a trapezoidal shape (**Figure 5a**), which is a diagnostic criterion of unilateral lambdoid synostosis (Huang et al. 1996:767-768). In unilateral plagiocephaly there is typically an occipito-parietal flattening.

Determination of the severity of plagiocephaly requires measurements of the cranium (**Figure 5b**). The distance from the occipital flattening to the contralateral forehead is much shorter than its cotralateral counterpart (lines A and B); the head shape is asymmetric and is disproportionately short. In addition to the right unilateral lambdoid synostosis, the cranium shows an occipitomastoid bulge. A groove was observed on the anterior aspect of the occipital condyle on the left and right sides (**Figure 5c**). Occipital condyles are asymmetric. Multiple elevations were noted on the facets. The surface of the facets was rough and serrated and they were bipartite (**Figure 5d**).

This is the first documented case of possible plagiocephaly in Armenia. Despite all these congenital deformities, this individual survived into adulthood, suggesting that his pathological condition was not an impediment in the life.

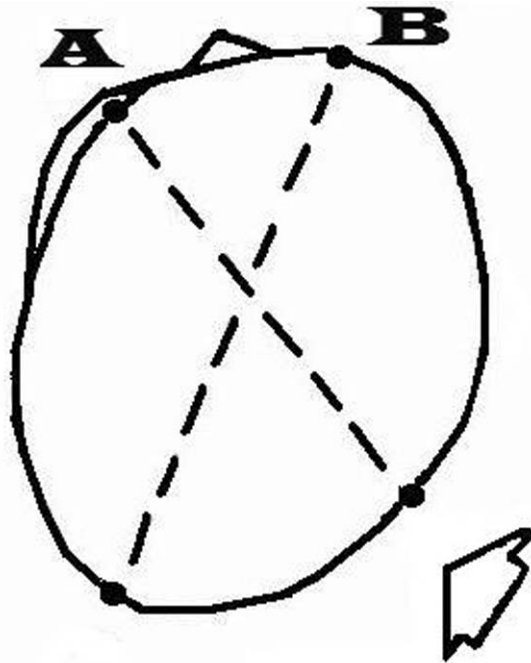
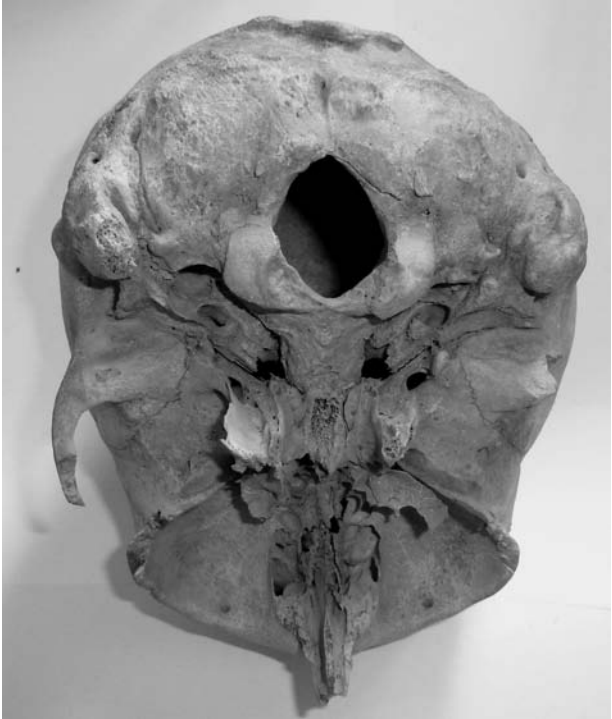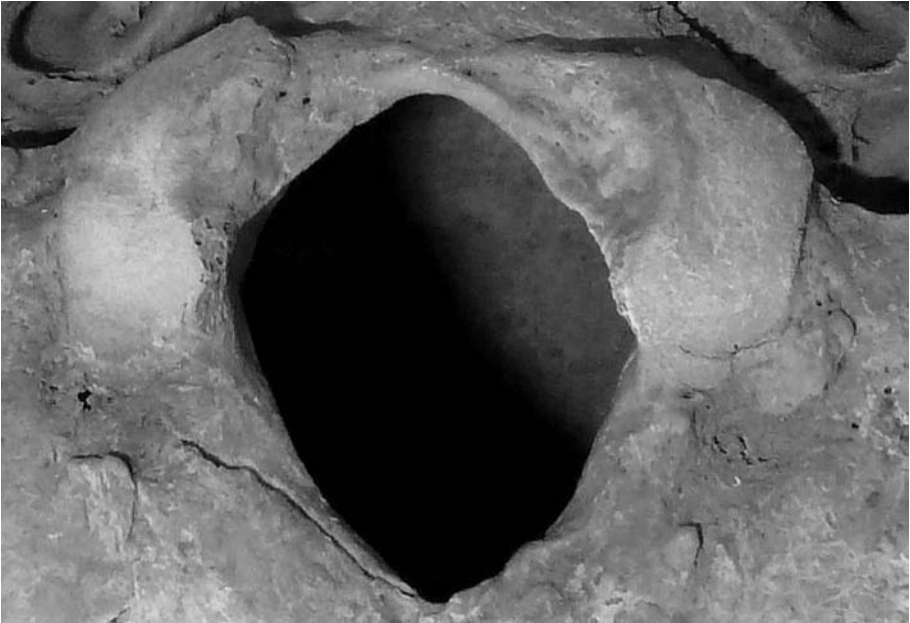


Figure 5. Plagiocephaly, (a) calvaria and right lambdoid suture, (b) difference between fronto-occipital diagonals. Vardbakh, burial 5/2.



c



d

Figure 5. Plagioccephaly, (c) basal view, (d) asymmetrical occipital condyles. Vardbakh, burial 5/2.

Degenerative joint disease

The most advanced case of OA was observed on the elbows of an individual from Black Fortress I (burial 40, female, 41–46 years, **Figure 6a**). An erosive area is present on the right olecranon. The distal end of the right ulna also shows a porous alteration. The cervical vertebrae show signs of DJD both on the bodies (flat osteophytes on the edges and porous plates) and on the intervertebral facets (some of them are porous and irregularly enlarged, **Figure 6b**). Also, the margins of the glenoid cavity show osteophytes (**Figure 6c**).

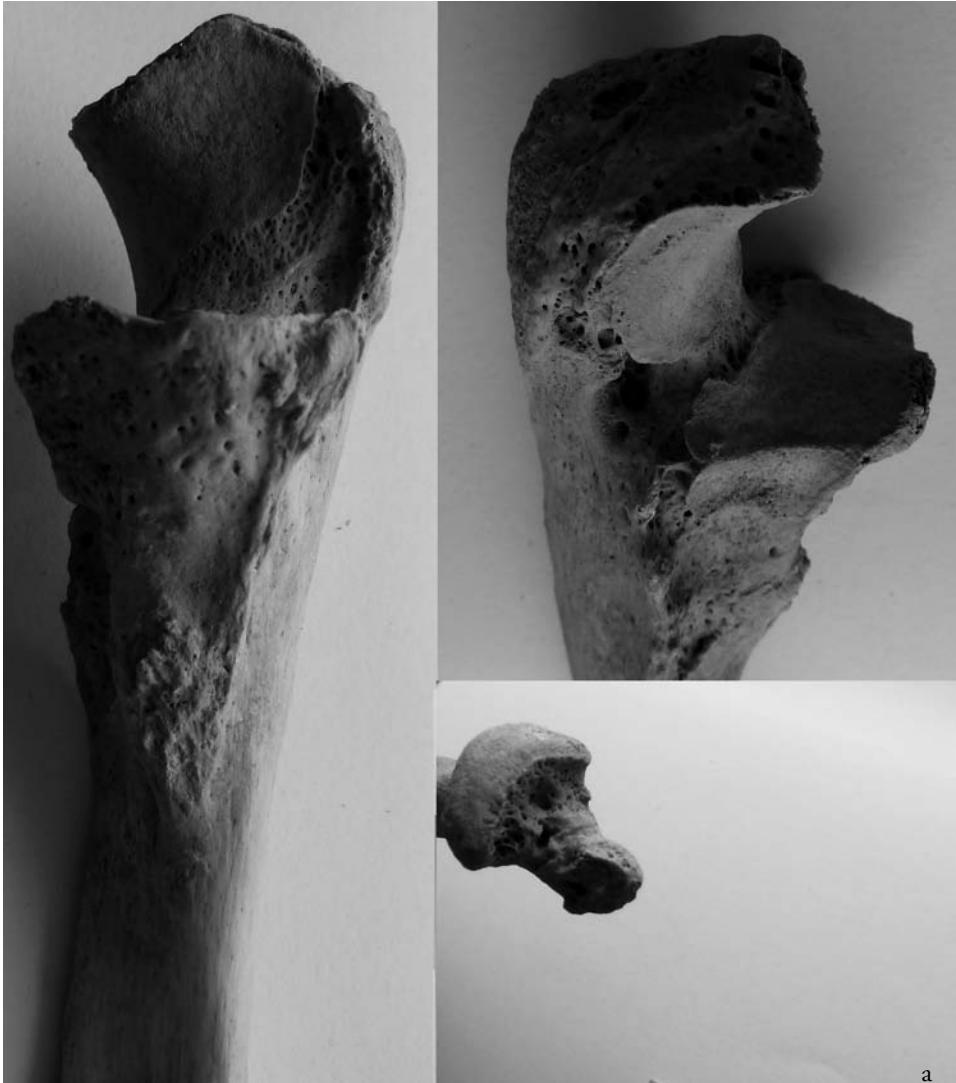

Figure 6. Degenerative joint disease, (a) ulna. Black Fortress I, burial 4.




Figure 6. Degenerative joint disease, (b) cervical vertebrae, (c) scapula. Black Fortress I, burial 4.

Osteoarthritic changes in synovial joints affected a total of 4/12 individuals in the historic population from Vardbakh. Two of those that suffered from OA were young adults, and two were middle-age adults. In the Black Fortress I population, OA was observed in 5/23 individuals. In Beniamin, nineteen adults (20.5%) exhibited osteoarthritic change, among them 14 females and 5 males (Khudaverdyan 2000, 2010).

Many cases of deforming spondylosis were revealed in the Benjamin cemetery. The prevalence was higher in males (19.4%) than in females (12.9%). In Vardbakh, only one male exhibited spondylosis. In the skeletal sample from the Black Fortress I, two females were found to be affected by spondylosis.

Dental diseases

No dental pathology was observed in the subadults from both investigated sites. The frequencies of various types of dental disease in adults are presented in **Table 2**.

At Black Fortress I, nine adult individuals showed evidence of dental abscesses, which was higher than in the Vardbakh population where only one individual was affected. The molars were more commonly affected by abscesses, followed by the premolars and incisors. On average, there were more dental abscesses in the maxillary dentition compared to the mandible.

Periodontal disease was the most common dental pathology observed at Black Fortress I. Seven out of twenty-three observable dentitions (30.5%) exhibited some form of alveolar bone loss. As a whole, the most severely affected teeth were the premolars and molars. On average, there was greater bone loss in the mandible than in the maxilla. The frequency of periodontal disease was comparable at Vardbakh where five out of twelve dentitions (41.7%) showed evidence of alveolar bone loss. The most severely affected teeth in this group were the premolars, followed by the molars.

Antemortem tooth loss was a frequent finding in the dentitions at Black Fortress I. Six adult individuals met the criteria for antemortem tooth loss. Maxillary teeth were more often affected than the mandibular dentition. At Vardbakh, antemortem tooth loss was observed in three adult individuals. The mandibular teeth were more commonly affected than the maxillary teeth. The rate of loss, however, may not be entirely representative of an oral pathological condition. Furthermore, antemortem tooth loss is age-progressive, as rates of tooth loss increase with age.

Wear extending into dentine, often with secondary dentine or exposure of the dental pulp, was common at Benjamin (Khudaverdyan 2000). The average dental wear in the dentition of individuals from Black Fortress I was considerably lower than at Benjamin. Interestingly, one individual from Vardbakh (burial 4, female) displayed an uneven pattern of wear on her first and second incisors. Uniform dental wear of the anterior teeth and bone development of the relief in chewing muscles attachments in this individual (**Figure 7**) suggest that dental wear was a consequence of functional load. This feature of the teeth may be associated either with malocclusion, or with the use of teeth for a non-masticatory activity (Merbs 1983; Erdal 2008). Other dentitions within the group displayed a generally flat, even rate of wear.

A relative high frequency of dental caries was observed both in Black Fortress I (4/23) and Vardbakh (2/12, **Figure 7**). At the same time, individuals with carious lesions exhibited a higher frequency of dental abscesses. An increase in the availability of sugary foods and refined carbohydrates resulted in an increase in carious lesions in Armenian populations during the Late Antiquity (Khudaverdyan 2005).

Calculus was recorded on the teeth of 15/23 individuals in the Black Fortress I sample. This was graded as minimal in five individuals, as slight in seven others, and as moderate in three. In the Vardbakh sample, calculus was present in 7/12 individuals. It ranged in severity from slight (n=2), through moderate (n=3), to considerable (n=2). The most severely affected

teeth were the molars, premolars, canines, followed by the incisors. Such levels of calculus are almost certain to have contributed to the relatively high percentage of periodontal disease (cf. Roberts & Manchester 1997).

Table 2. Dental pathology (affected/observed teeth)

Pathology	Site	Sex	Position	I1	I2	C	P1	P2	M1	M2	M3	
Dental Abscess	Black Fortress I	F	Maxilla	2/13		0/13		2/13		5/13		
			Mandible	0/13		0/13		1/13		1/13		
		M	Maxilla	0/10		0/10		1/10		4/10		
			Mandible	1/10		0/10		0/10		2/10		
	Vardbakh	F	Maxilla	0/7		0/7		0/8		1/8		
		M		0/4		0/4		0/4		0/3		
Periodontal Disease	Black Fortress I		Maxilla	1/13	0/13	0/13	1/13	1/7	0/13	3/12	0/12	
			Mandible	0/16	0/12	0/13	0/14	0/13	1/14	1/13	1/14	
	Vardbakh		Maxilla	1/9	0/7	0/9	1/7	2/7	0/8	0/8	0/7	
			Mandible	1/4	0/6	0/5	0/4	0/6	1/8	1/7	1/8	
	Antemortem Tooth Loss	Black Fortress I		Maxilla	1/13	0/19	0/10	2/13	2/19	4/13	5/13	4/19
				Mandible	0/7	0/12	1/17	1/15	3/11	1/18	4/12	4/14
Vardbakh			Maxilla	2/9	2/10	2/9	1/8	2/9	2/11	3/9	4/11	
			Mandible	0/6	0/6	1/8	1/6	2/7	2/8	1/7	2/7	
Dental Caries	Black Fortress I	M	Maxilla	0/7	0/9	0/9	0/19	0/10	0/8	2/10	0/9	
		M	Mandible	0/5	0/7	0/7	0/8	0/7	0/7	1/9	0/8	
	Black Fortress I	F	Maxilla	0/9	0/10	0/7	0/9	1/11	0/9	1/10	0/9	
		F	Mandible	0/7	0/9	0/7	0/9	0/9	0/7	0/8	0/7	
	Vardbakh	M	Maxilla	0/3	0/3	0/3	0/4	0/3	1/4	0/3	0/2	
		M	Mandible	0/3	0/4	0/4	0/3	0/3	0/4	0/3	0/3	
	Vardbakh	F	Maxilla	0/7	0/6	0/6	0/7	0/7	0/7	0/6	0/6	
		F	Mandible	0/6	0/6	1/6	0/7	0/7	0/7	0/7	0/5	
Dental Calculus	Black Fortress I		Maxilla	9/19	7/19	11/11	12/17	12/19	14/18	15/19	8/19	
			Mandible	7/17	10/12	10/17	14/15	13/18	12/18	14/19	7/14	
	Vardbakh		Maxilla	4/9	6/11	5/7	5/8	6/9	7/10	6/10	5/11	
			Mandible	5/7	4/6	6/8	6/6	7/7	7/8	7/8	5/7	

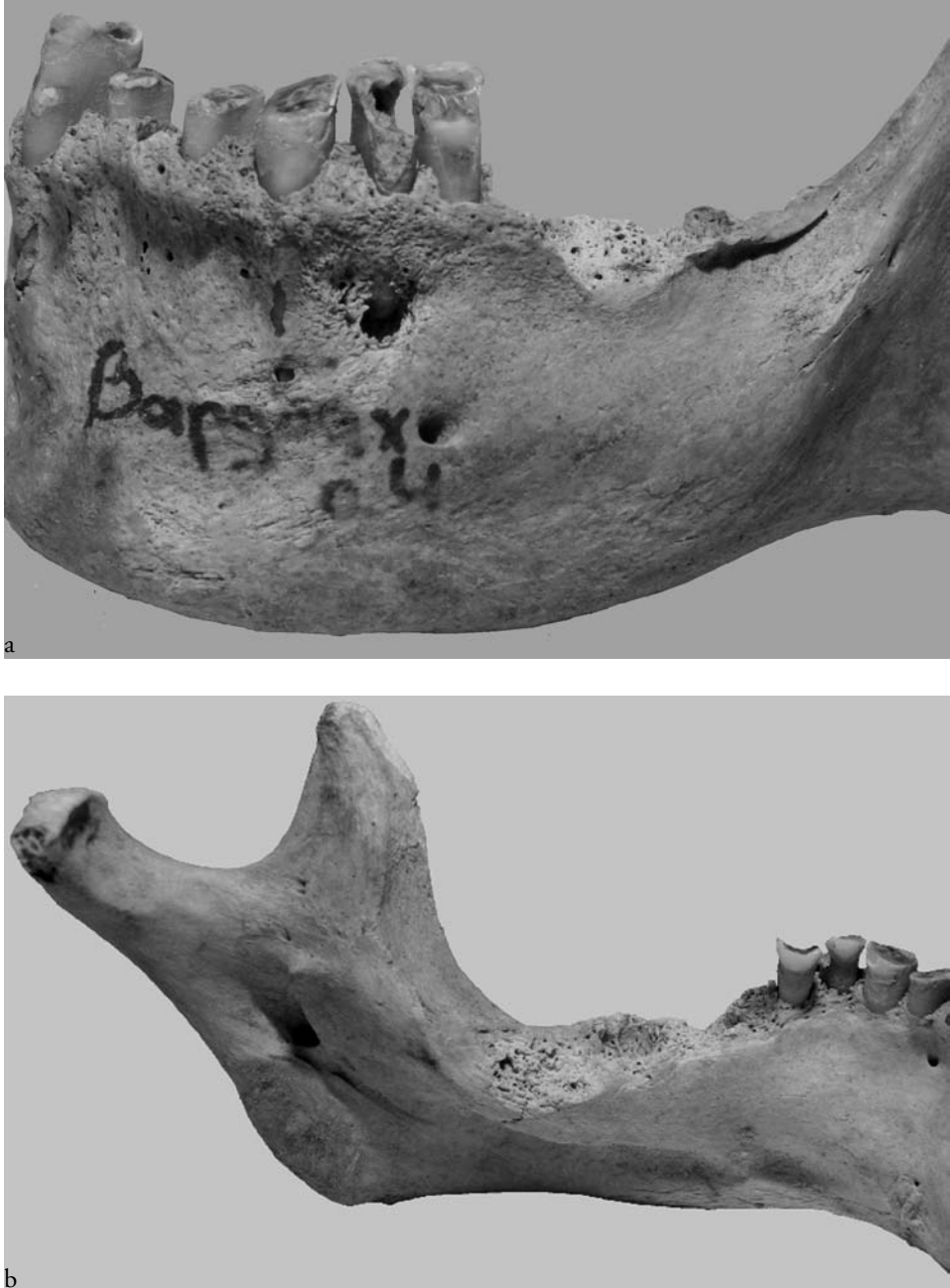


Figure 7. Dental pathology (dental caries, antemortem tooth loss and dental abscess), (a) buccal view of left mandible, (b) lingual view of left mandible. Vardbakh, burial 4.

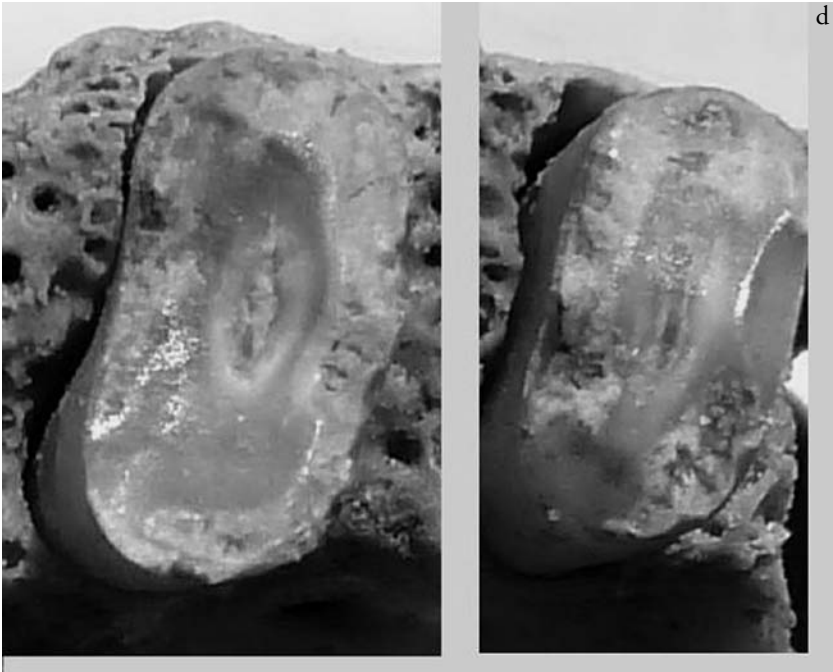
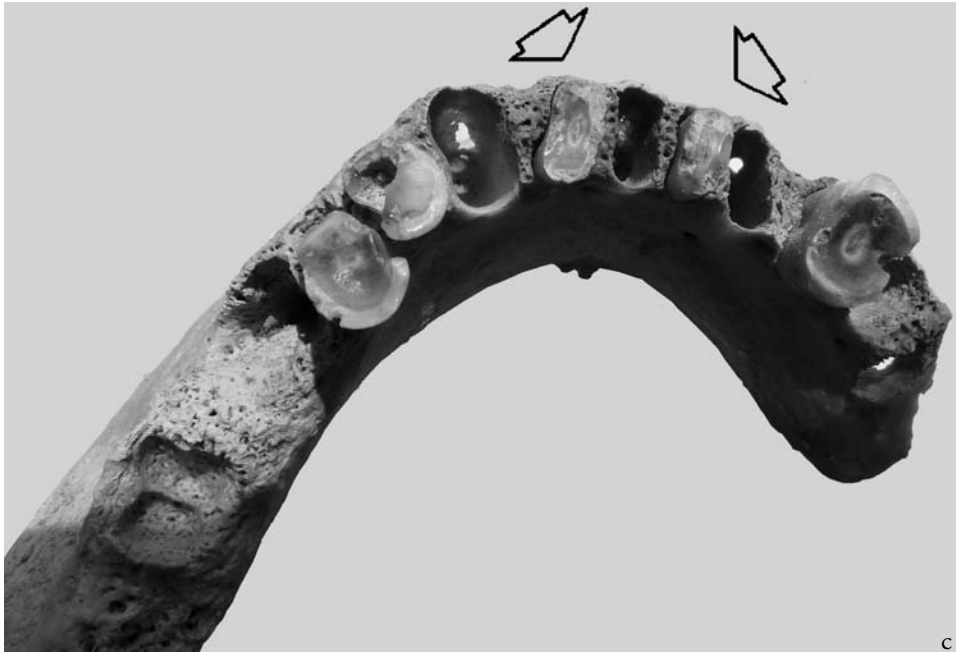


Figure 7. Dental pathology (dental caries, antemortem tooth loss and dental abscess), (c) occlusal view, (d) pattern of wear in two lower incisors. Vardbakh, burial 4.

A case of artificial cranial modification

So far, in the territory of contemporary Armenia, artificial cranial deformation has been observed in single individuals from the archaeological sites of Beniamin, Shirakavan and Karmarakar (Khudaverdyan 1997, 2009b, 2011). These skulls had an high form of the annular type of cranial deformation. They had been bound with a 2cm-wide bandage, which had been tied around the forehead, the parietal bones, and the squama occipitalis. Due to circular pressure, the head had grown upward and had acquired an approximately cone shaped form, with an apparent depression in the middle of the squama frontalis and a flattened squama occipitalis.

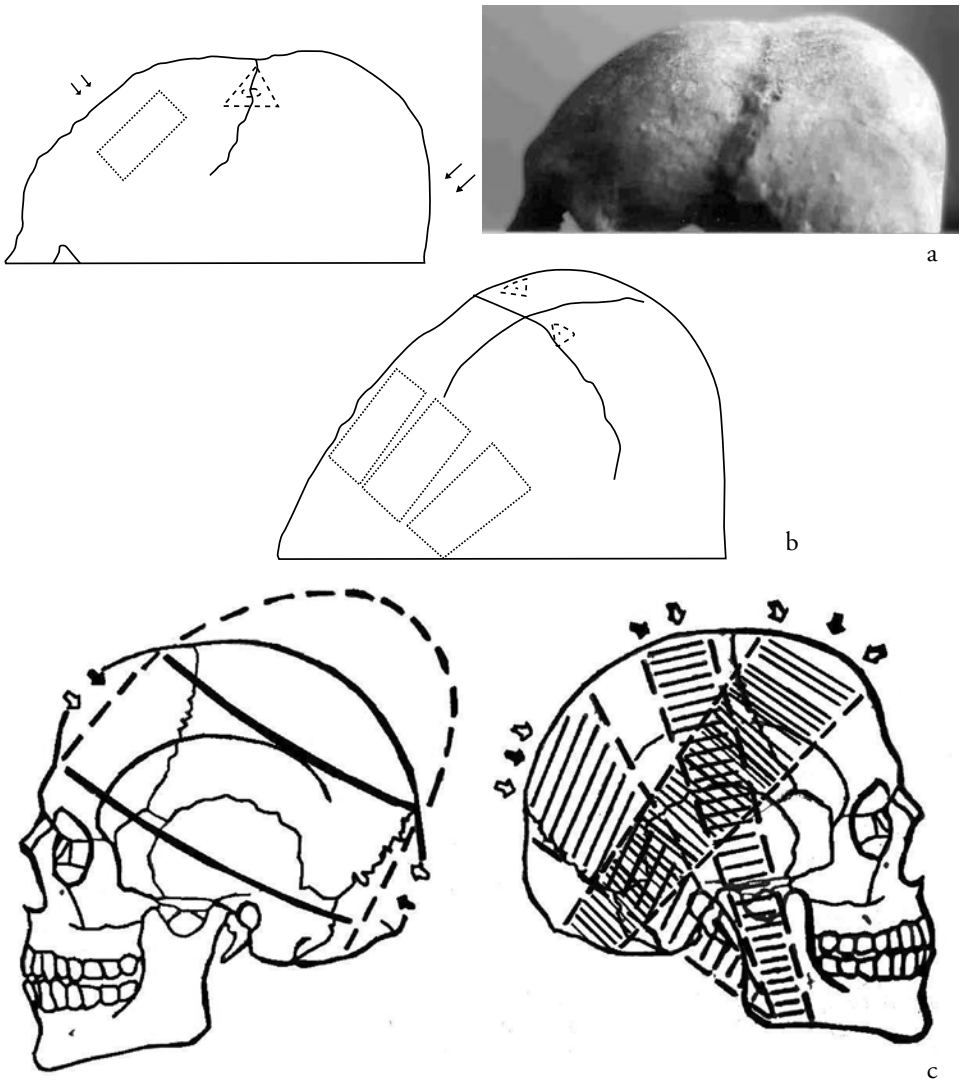


Figure 8. Artificial cranial modification, (a) lateral view, (b) location of points of pressure (headress?) on skull, (c) reconstruction of head bandaging. Vardbakh, burial 3.

In addition, an artificially deformed cranium was observed in the skeleton of a mature adult male from Vardbakh (**Figure 8a**). Some morphological changes to the neurocranium, e.g., a strongly flattened, elevated, and elongated frontal bone; a shortened occipital bone; and a flattened lower part of the squama occipitalis with a smooth relief suggest that the deformation may have been caused by a combined circular bandage that had exerted pressure in the direction from front to back and from the upper to the lower part. The bandage had caused shortening of the cranium and had enlarged its height; an oblique form of the so-called annular type. In the crossing points of the sagittal and the coronal sutures, two depressions (0.5–0.7mm) were observed (**Figure 8b**). Coupled with a pronounced flattening and slant of the occipital bone, this finding suggests the use of a head-shaping device attached with ligatures to the cranium during childhood (**Figure 8c**). As the pressure of such bindings on a head was long and severe enough to produce a bony reaction, it is possible to assume that the device attached to the head carried out the role of a headdress (Khudaverdyan 2011)—an ornament or a cult object, perhaps as a sign of social difference.

The use of artificial cranial modification in Armenia during Late Antiquity may have been related to the emerging social complexity and attests to the need to differentiate among people, creating a niche for such a highly visual bodily marker (Khudaverdyan 2000, 2011).

Conclusion

The Shiraksky plateau was an ecologically favorable place for human populations as it offered a diversity of products for a balanced subsistence. Palaeopathological examination revealed that the inhabitants in this area in Late Antiquity were subject chiefly to trauma, osteoarthritis, and dental diseases such as abscesses and periodontal disease. Many individuals exhibited trauma to the skull which may have been related to interpersonal violence (Khudaverdyan 2000, 2010). The population lacked oral hygiene. Dental abscesses have an important role in infectious processes, as they are propitious for the development of the bacteria that cause infection, not only in the alveolar bone but also in the rest of the body. Dental wear was less severe at Black Fortress I, although dental abscesses and AMTL were more prevalent. In contrast, periodontal disease and AMTL of the molars were more prevalent at Vardbakh, although the small sample size may be a factor. There was evidence for possible non-masticatory dental wear in one individual from Vardbakh.

The Black Fortress I population was somewhat less prone to the development of osteoarthritis of the long bones than the people buried in the Vardbakh cemeteries. The explanation, perhaps, is related to the more strenuous physical activity undertaken by the people at Vardbakh and/or differences in the age or sex of the populations. There was one individual from Vardbakh displaying craniocostosis and another with an artificially deformed skull. Although the sample size was small in the case of both sites, bioarchaeological data from the studied historical population of Black Fortress I and Vardbakh are useful in understanding the lifeways of the ancient Armenian population.

Acknowledgements

Many people contributed to this paper. I would like to express my deepest gratitude to my family—my mother Haykui, my brothers Hayk, Ryben and Syren for all that they have done for me. Special thanks are also due to my wonderful teacher, Professor Vasily E. Deriabin (Moscow) for all of his help, encouragement, and confidence in me. I would like to thank Stepan Ter-Markaryan (Gyumri) and members of the archaeological expeditions for the opportunity to study the human remains from their collections. I also thank Dr. Tina Jakob (Durham) and Professor Maria Dobrovolskaya (Moscow) who provided constructive comments on this paper.

References

- Abdueshvili M.G. (1982), *Anthropology of the population of the Caucasus in the Bronze Age*, Tbilisi: Metsniereba.
- Alekseev V.V. (1974), *Origin of the people of Caucasus*, Moscow: Science.
- Arakelyan V.N. (1976), *Ocherki po istorii iskusstva drevnei Armenii (VI v. do n.e. – III v. n.e.)* [Outline of the history of ancient Armenian art, 6th century BC – 3rd century AD], Yerevan: National Academy of Science of Armenia.
- Avagyan I. (2003), “*Sev Amroci*” *hushardcani dambaranadasht* [Black Fortress site and cemetery] [in: “Hayastani hnaguin mshakyit” [The ancient culture of Armenia], A. Qalantaryan, R. Badalyan (ed.), Yerevan: Mukhni, pp. 128-134.
- Bridges P.S. (1992), *Prehistoric arthritis in the Americas*, *Annual Review of Anthropology* 21:67-91.
- Brothwell D. (1981), *Digging up bones*, London: British Museum of Natural History.
- Buikstra J.E., Ubelaker D.H., ed. (1994), *Standards of data collection from human skeletal remains*, „Arkansas Archaeological Survey Research Series” 44, Fayetteville.
- Byers S. (2002), *Introduction to forensic anthropology: A textbook*, Boston: Auyn & Bacon.
- Clarke N.G. (1990), *Periodontal defects of pulpal origin: Evidence in early man*, *American Journal of Physical Anthropology* 82:371-376.
- Cohen M.M., MacLean R.E. (2000), *Craniosynostosis. Diagnosis, evaluation and management*, New York: Oxford University Press.
- Erdal Y.S. (2008), *Occlusal grooves in anterior dentition among Kovuklukaya inhabitants (Sinop, Northern Anatolia, 10th century AD)*, *International Journal of Osteoarchaeology* 18:152-166.
- Eganyan L.G. (2010), *Arkheologicheskoe i istoriko-etnograficheskoe issledovanie Shiraka* [Archaeological and historical-ethnographic research in Shirak], vol. 1, Yerevan-Gyumri: Science and Chirak Centre of Armenian Studies.
- Filer J.M. (1997), *Ancient Egypt and Nubia as a source of information for cranial injuries* [in: “Material harm: Archaeological studies of war and violence”, J. Carman (ed.), Glasgow: Criuthne Press, pp. 47-74.
- Galloway A. (1999), *Broken bones: Anthropological analysis of blunt force trauma*. Springfield, Illinois: Charles C. Thomas Publisher, Ltd.
- Gault D.T., Renier D., Marchac D., Jones B.M. (1992), *Intracranial pressure and intracranial volume in children with craniosynostosis*, *Plastic Reconstruction Surgery* 90:377-381.

- Gilbert B.M, McKern T.W. (1973), *A method for aging the female os pubis*, American Journal of Physical Anthropology 38:31-38.
- Goodman A., Martin D. (1993), *Reconstructing health profiles from skeletal remains* [in:] "The backbone of history: Health and nutrition in the western hemisphere", R.H. Steckel, J.C. Rose (ed.), Cambridge: Cambridge University Press, pp. 11-60.
- Goodman A.H., Martin D.L., Armelagos G.J., Qark G. (1984), *Indications of stress from bones and teeth* [in:] "Paleopathology at the origins of agriculture", M.N. Cohen, G.J. Armelagos (ed.), New York: Academic Press, pp. 13-49.
- Hartnady P., Rose J.C. (1991), *Abnormal tooth-loss patterns among Archaic-Period inhabitants of the Lower Pecos Region, Texas* [in:] "Advances in dental anthropology", M.A. Kelley, C.S. Larsen (ed.), New York: Wiley-Liss, pp. 267-278.
- Herrera D., Roldan S., Gonzales I., Sanz M. (2000), *The periodontal abscess (I): Clinical and microbiological findings*, Journal of Clinical Periodontology 27:387-394.
- Hewsen R.H. (1997), *The geography of Armenia* [in:] "The Armenian people from ancient to modern times", vol. 1, R.G. Hovannisian (ed.), New York: St. Martin's Press, pp. 1-17.
- Hildebolt C.F., Molnar S. (1991), *Measurement and description of periodontal disease in anthropological studies* [in:] "Advances in dental anthropology", M.A. Kelly, C.S. Larsen (ed.), New York: Wiley-Liss, pp. 225-240.
- Hillson S. (1996), *Dental anthropology*, Cambridge: Cambridge University Press.
- Hillson S. (2008), *Dental pathology* [in:] "Biological anthropology of the human skeleton", M.A. Katzenberg, S.R. Saunders (ed.), 2nd ed., Hoboken, NJ: John Wiley & Sons, pp. 301-340.
- Huang M.H.S., Gruss J.S., Clarren S.K., Mouradian W.E., Cunningham M.L., Roberts T.S., Loeser J.D., Cornell C.J. (1996), *The differential diagnosis of posterior plagiocephaly: true lambdoid synostosis versus positional molding*, Plastic Reconstructive Surgery 98:765-774.
- Jurmain R.D. (1999), *Stories from the skeleton: Behavioral reconstruction in human osteology*, Amsterdam: Gordon and Breach Publishers.
- Kabbani H., Raghuvver T.S. (2004), *Craniosynostosis*, Journal of American Family Physician 69:2863-2870.
- Katz D., Suchey J.M. (1986), *Age determination of the male os pubis*, American Journal of Physical Anthropology 69:427-435.
- Khudaverdyan A.Y. (1997), *The artificial-deformed skulls and teeth from burials of antique burial ground Beniamin*, The Bulletin of Social Studies. Armenian Academy of Sciences 2 (595):138-144.
- Khudaverdyan A.Y. (2000), *Naselenie Armyanskogo nagora v antichnuuy epokhu (po antropologicheskim dannim Beniaminskogo mogilnika)* [The population of the Armenian uplands during Antiquity, based on data from the Beniamin cemetery], Yerevan: Tigran Mec.
- Khudaverdyan A.Y. (2005), *Atlas paleopatologicheskikh nakhodok na territorii Armenii* [Atlas of paleopathological finds in the territory of Armenia], Yerevan: Van Aryan.
- Khudaverdyan A.Y. (2009a), *Naselenie Armyanskogo nagora v epokhu bronzi. Etnogenez i etnicheskaya istoriya* [The Bronze Age population of Armenian highland. Ethnogenesis and ethnic history], Yerevan: Van Aryan.
- Khudaverdyan A.Y. (2009b), *Origin of the Armenian people in the light of data paleoanthropology*, Ethnographic Review (Moscow) 5:99-119.

- Khudaverdyan A.Y. (2010), *Pattern of disease in three 1st century BC – 3rd century AD burials from Beniamin, Vardbakh and the Black Fortress I, Shiraksky plateau (Armenia)*, Journal of Paleopathology 22:15-41.
- Khudaverdyan A.Y. (2011), *Artificial modification of skulls and teeth from ancient burials in Armenia*, Anthropos 106(2):1-7.
- Larsen C.S. (1997), *Bioarchaeology: Interpreting behavior from the human skeleton*, Cambridge: Cambridge University Press.
- Lovejoy C.O., Meindl R.S., Pryzbeck T.R., Mensforth R.P. (1985), *Chronological metamorphosis of the auricular surface of the ilium: A new method for the determination of adult skeletal age at death*, American Journal of Physical Anthropology 68:15-28.
- Lovell N.C. (1997), *Trauma analysis in paleopathology*, Yearbook of Physical Anthropology 40:139-170.
- Mandel I. (1995), *Calculus update: prevalence, pathogenecity, and prevention*, Journal of American Dental Association 126:573-580.
- Martirosyan A.A. (1964), *Armenia during of Bronze Age and Early Iron*, Erevan: National Academy of Science of Armenia.
- Mays S. (1998), *The archaeology of human bones*, New York: Routledge.
- Meindl R.S., Lovejoy C.O., Mensforth R.P., Carlos L.D. (1985), *Accuracy and direction of error in the sexing of the skeleton: Implications for paleodemography*, American Journal of Physical Anthropology 68:79-85.
- Merbs C.F. (1983), *Patterns of activity-included pathology in a Canadian Inuit population*, "Archaeological Survey of Canada. Mercury Series" 119. Ottawa: National Museum of Man.
- Moorrees C.F., Fanning E.A., Hunt E.E. (1963a), *Formation and resorption of three deciduous teeth in children*, American Journal of Physical Anthropology 21:205-213.
- Moorrees C.F., Fanning E.A., Hunt E.E. (1963b), *Age variation of formation stages for ten permanent teeth*, Journal of Dental Research 42(6):1490-1502.
- Nafté M. (2000), *Flesh and bone: An introduction to forensic anthropology*. Durham NC: Carolina Academic Press.
- Ortner D.J. (2003), *Identification of pathological conditions in human skeletal remains*. 2nd edition, London: Academic Press.
- Phenice T.W. (1969), *A newly developed visual method of sexing the os pubis*, American Journal of Physical Anthropology 30:297-302.
- Piotrovsky B.B. (1959), *Vanskoe carstvo (Urartu)* [Kingdom on the Van Lake, Urartu], Moscow: East Literature.
- Roberts C. (1991), *Trauma and treatment in the British Isles in the historic period: A design for a multidisciplinary research* [in:] "Human paleopathology: Current syntheses and future options", D.J. Ortner, A.C. Aufderheide (ed.), Washington: Smithsonian Institution Press, pp. 225-240.
- Roberts C., Manchester K. (2005), *The archaeology of disease*. 3rd edition, Ithaca: Cornell University Press.
- Sager P. (1969), *Spondylosis cervicalis: A pathological and osteoarchaeological study of osteochondrosis intervertebralis cervicalis, arthrosis uncovertebralis, and spondylarthrosis cervicalis*, Copenhagen: Munksgaard.
- Sauer N.J. (1998), *The timing of injuries and manner of death: Distinguishing among antemortem, perimortem, and postmortem trauma* [in:] "Forensic osteology: Advances in the

- identification of human remains”, K.J. Reichs (ed.), 2nd edition, Springfield IL: Charles C. Thomas, pp. 321-332.
- Scott E.C. (1979), *Dental wear scoring technique*, American Journal of Physical Anthropology 51:213-218.
- Smith B.H. (1984), *Patterns of molar wear in hunter-gatherers and agriculturalists*, American Journal of Physical Anthropology 63:39-56.
- Smith P. (1972), *Diet and attrition in the Natufians*, American Journal of Physical Anthropology 37:233-238.
- Smith P. (1989), *Paleonutrition and subsistence patterns in the Natufians* [in:] “People and culture in change. Proceedings of the second symposium on Upper Paleolithic, Mesolithic and Neolithic populations of Europe and the Mediterranean basin”, I. Hershkovitz (ed.), BAR International Series 508, Oxford: Archaeopress, pp. 375-384.
- Smith P., Bar-Yosef O., Sillen A. (1984), *The archaeological and skeletal evidence for dietary changes during the Late Pleistocene/Early Holocene in the Levant* [in:] “Paleopathology at the origins of agriculture”, M. Cohen, G. Armelagos (ed.), New York: Academic Press, pp. 101-136.
- Smith P., Kolska-Horwitz L. (1998), *Culture, environment and disease: Paleo-anthropological findings for the Southern Levant* [in:] “Digging for pathogens”, C.L. Greenblatt (ed.), Rehovot: Balaban Publishers, pp. 201-239.
- Ter-Markaryan S. (1991), *Kumai tangarani Vardbakh dambaranadashti peghumner* [Excavation of employees of museum “Gumry” at ancient Vardbakh cemetery] [in:] “Scientific session devoting to results of field archaeological researches in Republic of Armenia”, G. Tiratsyan (ed.), Yerevan: Institute of Archaeology and Ethnography, pp. 79-80.
- Ter-Markaryan S., Avagyan I. (2000), “*Sev Berd*” *hushardcani bnakatex ev dambaranadasht* [Site and cemetery Black Fortress] [in:] “Shiraki patmamshakytayin dzarangtyun” [Shirak’s historical and cultural heritage], S. Hairapetya (ed.), Gyumri: Gitutyun, pp. 9-11.
- Tiratsyan G.A. (1988), *Kyltyra drevnei Armenii VII v. do n.e. – III v. n.e. (po arkheologicheskim dannim)* [Culture of ancient Armenia, 7th century BC – 3rd century AD, after archaeological data], Yerevan: National Academy of Science of Armenia.
- Turner C.G., Nichol C.R., Scott G.R. (1991), *Scoring procedures for key morphological traits of the permanent dentition: the Arizona State University Dental Anthropology System* [in:] “Advances in dental anthropology”, M.A. Kelley, C.S. Larsen (ed.), New York: Wiley-Liss, pp. 13-31.
- Ubelaker D. (1989), *Human skeletal remains. Excavation, analysis, interpretation*, Washington: Taraxacum.
- Walker P.L. (1997), *Wife beating, boxing, and broken noses: Skeletal evidence for the cultural patterning of violence* [in:] “Troubled times. Violence and warfare in the past. War and society”, D.L. Martin, D.W. Frayer (ed.), vol. 3, Amsterdam: Gordon & Breach Publishers, pp. 145-179.
- Williams B.L., McCann G.F., Schoenknecht F.D. (1983), *Bacteriology of dental abscesses of endodontic origin*, Journal of Clinical Microbiology 18:770-774.