

## The people of Early Byzantine Maroneia, Greece (5<sup>th</sup>–6<sup>th</sup> c. AD)

Paraskevi Tritsaroli<sup>\*1</sup>, Chryssa Karadima<sup>2</sup>

<sup>1</sup> The Malcolm H. Wiener Laboratory for Archaeological Science,  
American School of Classical Studies,  
54 Souidias Str., Athens, GR-106 76, Greece  
email: voula\_tritsaroli@hotmail.com (corresponding author)

<sup>2</sup> Ephorate of Antiquities of Rodopi,  
4 A. Symeonidi Str., GR-691 32 Komotini, Greece

---

**Abstract:** *This study reports on the human remains of 39 individuals uncovered at the Early Byzantine cemetery of Maroneia in Thrace, Greece (5<sup>th</sup>–6<sup>th</sup> c. AD). Results on physiological and activity related stress indicators do not show deteriorating living conditions caused by major geopolitical transformation, social upheavals or natural disasters but rather a peasant lifestyle and adequate diet. The sample includes two individuals with intentional cranial modification, a practice that was not customary in Christian tradition. Biocultural evidence supports the hypothesis that these individuals had a cultural origin which was linked to the Huns. The combined analysis of historical, archaeological and skeletal data allows interpretations of health, lifestyle and biosocial complexity during Early Christian times in Greece.*

**Key words:** health; disease; cranial modification; Thrace; Early Byzantine period

### Introduction

The history of the Byzantine Empire during Late Antiquity (4<sup>th</sup>–7<sup>th</sup> c. AD) includes continuous geopolitical changes, and major administrative, social and cultural transformations. The reforms of Diocletian (284–305 AD) and Constantine I the Great (324–337 AD) lead to what is called the fourth-century revival (Laiou 2002: 11). The recognition of Christianity in 313 AD and the foundation of Constantinople on 11<sup>th</sup> May 330 AD are the two fundamental reforms for the history of the eastern part of the Empire. The fourth and fifth centuries AD were a period of wars; the Empire had to deal with extensive barbarian raids on many fronts and problems emerging due to insecurity, defence and subsistence (Cameron 1993; Mango 1980; Mitchell 2007; Morrisson & Sodini 2002; Ostrogorsky 1969). In addition, continuous controversies existed between various religious movements, theological doctrines, and the supporters of the orthodox faith. Despite all these phenomena, the late fifth and the

sixth centuries were a turning point for the Byzantine State. The reign of Justinian I was a period of significant political, cultural, and artistic reforms, important building activity, considerable industrial production and extended commercial networks. Within this period of euphoria and progress, the Empire had to defend its frontiers against incessant raids; these phenomena often interacted with episodes of famines and epidemics such as the plague of 541-542 AD that caused a serious demographic crisis (i.e., increased mortality) (Sołtysiak 2006; Stathakopoulos 2004: 139-141). The following years to the end of the 7<sup>th</sup> c. AD introduced a period of general decline, the extent of the Empire reduced significantly and many changes occurred at the economic and political level (Laiou 2002: 14).

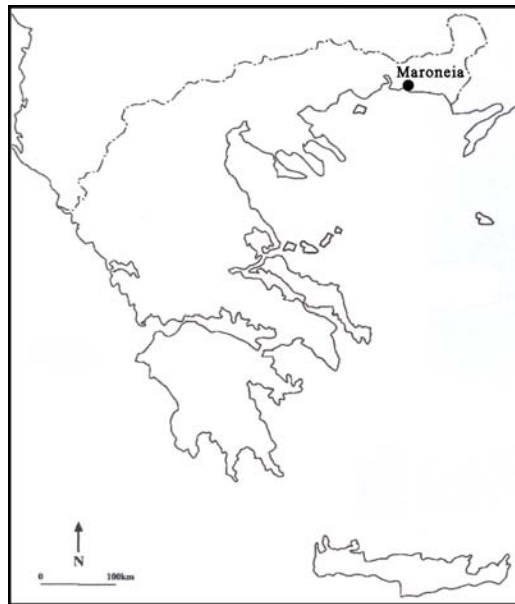

Figure 1. Map of Greece showing the location of Maroneia

During this period, the state's provinces were reorganized and grouped into dioceses. The system of dioceses ceased to operate effectively in the 5<sup>th</sup> c. AD and finally disappeared in the 7<sup>th</sup> c. AD. This study is concerned with the Diocese of Thraciae that included the regions of Europa, Thracia, Haemimontus, Rhodope, Moesia II and Scythia (Kazhdan 1991: 2079). Like the rest of the Empire, in the 4<sup>th</sup> through 7<sup>th</sup> c. AD the diocese of Thrace was invaded by Goths, Huns, Slavs and other groups; it was the Slavs and Bulgars who settled in the area and after the extensive devastation of almost all the cities, the Thracian population retreated to the mountains (Kazhdan 1991: 2079-2080).

Among major cities in the region of Thrace such as Maximianopolis, Anastasioupolis, Trajanoupolis, Diokletianopolis, Philippopolis, Sebastopolis, Augusta Trajana, and Diospolis, the city-state of Maroneia was for many centuries (7<sup>th</sup> c. BC – 13<sup>th</sup> c. AD) an important harbor and commercial center of the Northern Aegean, at the crossroads between the West and the East (**Figure 1**). Because of its geographical positioning and the advantages of the natural environment (e.g., fertile soil), Maroneia developed a mixed subsistence based on agrarian economy, industry and trade. Despite the incessant upheavals and invasions that disrupted the Diocese of Thrace and the Empire in general, Maroneia was never abandoned by its inhabitants (further information on Maroneia can be found in Doukata-Demertzi 2008; Karadima 2015; Karadima et al. 2015; Kardaras 2015; Popkonstantinov 2008).

This paper presents the results of the bioarchaeological analysis for the Early Byzantine cemetery sample of Maroneia (5<sup>th</sup>–6<sup>th</sup> c. AD). The aim is to analyze health and disease patterns of this urban population and place them into a broader geographical perspective through the comparison with other samples from Greece. In addition, the study describes two individuals with artificial cranial deformation. The purpose is to assess cranial modification as an indicator of regional interactions and cultural expansion, and examine the ways in which Early Byzantine society assimilated individuals who used this practice as a marker of sociocultural identity.

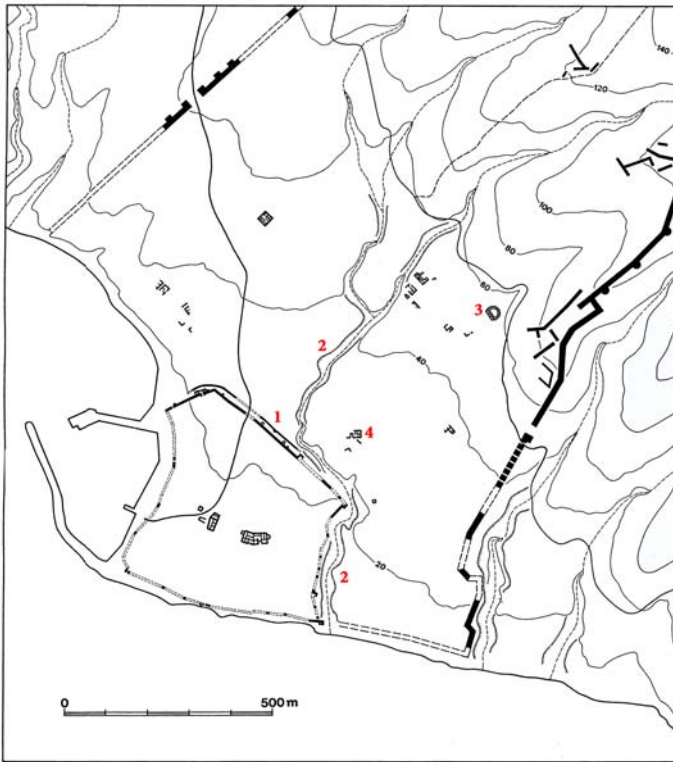
## Materials

Burial grounds have been identified both inside and outside the Byzantine city walls of Maroneia. The examined sample from the extramural cemetery presently includes 36 graves from the area of the ancient theatre and the area at the north and east of the fortified city (**Figure 2**). Cist, pit and tile graves were used. Thirty-three graves held one individual and three graves held two individuals. The deceased were oriented west–east, some of them with a slight northwest–southeast deviation, in a supine position with the forearms folded on the chest or abdomen, in accordance with the common Christian custom. The sample includes two individuals with cranial modification; both were individual primary burials without offerings and they were located on the west slope of the ancient theatre of Maroneia (Karadima 2015: 36–37).<sup>1</sup>

The sample contains 39 individuals (**Table 1**). The skeletal representation is moderate (36% on average) and cortical surfaces are well preserved (Brickley & McKinley 2004: 16, grade 0–1). The bones often show postmortem breaks which occurred either by taphonomic processes or during excavation and cleaning. This concerns particularly the crania and long bones, hindering cranial shape analysis and stature estimations. As a consequence, we were not able to obtain a complete set of metric

---

<sup>1</sup>The archaeological documentation is provided by CK, the second author.



**Figure 2.** Map of ancient Maroneia showing the location of (1) the Byzantine fortification, (2) the Kambana stream, (3) the ancient theatre and (4) the extra muros Early Christian basilica. The burials were found within this area (archives of the Ephorate of Antiquities of Rodopi).

data for adult crania. Similarly, femora and tibiae were not preserved intact for all adults; only the femoral length was used for stature estimations (see below).

## Methods

### Demography, stature and paleopathology

Human skeletal remains were examined macroscopically under normal light conditions. Sex determination for adults was carried out using dimorphic aspects of the os coxae; emphasis was given to specific anatomical features such as the subpubic region (ventral arc, subpubic concavity, ischiopubic ramus ridge), the presence of a preauricular sulcus and the form of the greater sciatic notch (Buikstra & Ubelaker 1994:

16-19). Adult age-at-death was estimated from morphological changes of the pubic symphysis and auricular surface of the os coxae (Brooks & Suchey 1990; Meindl & Lovejoy 1989; Todd 1920, 1921). Both pubic symphysis scoring systems were used

**Table 1.** List of individuals from Early Byzantine Maroneia. M – male, M? – probable male, F – female, F? – probable female, I – indeterminate.

Grave	Location	Preservation	Age category	Sex	Stature
I	Kambana, Theatro	moderate	young-aged	F	
II	Kambana, Theatro	moderate	middle-aged	I	
III	Kambana, Theatro	moderate	adult	F	1.58m
IV	Kambana, Theatro	poor	adult	I	
V	Kambana, Theatro	moderate	young-aged	M?	
VI	Kambana, Theatro	poor	adult	I	
(no number)	Kambana, Theatro	poor	adult	I	
(no number)	Kambana, Theatro	good	middle-aged	M	1.68m
(no number)	Kambana, Theatro	good	young-aged	M?	1.70m
(no number)	Kambana, Theatro	moderate	middle-aged	F	
1 (1988)	Kambana, Theatro	poor	adult	I	
2 (1988)	Kambana, Theatro	poor	adult	I	
1 (1994)	Kambana, Theatro	moderate	adult	F?	
2 (1994)	Kambana, Theatro	poor	adult	I	
TI	Kambana, Stogiannidou	good	middle-aged	M	1.76m
K1	Kambana, Stogiannidou	good	old-aged	F	
THI	Kambana, Stogiannidou	moderate	child (4y±12m)	I	
1, 1.A	Kambana, Christoforou	moderate	adolescent (12y±30m)	I	
1, 1.B	Kambana, Christoforou	moderate	middle-aged	F	
2, 2.A	Kambana, Christoforou	moderate	young-aged	F	1.56m
2, 2.B	Kambana, Christoforou	good	adult	F?	1.59m
3, 3.A	Kambana, Christoforou	poor	middle-aged	M	
3, 3.B	Kambana, Christoforou	poor	adult	I	
4	Kambana, Christoforou	poor	adult	I	
5	Kambana, Christoforou	good	middle-aged	M	1.60m
10	Kambana, Christoforou	good	young-aged	M	1.75m
16	Kambana, Christoforou	good	middle-aged	F?	
19	Kambana, Christoforou	poor	adult	I	
20	Kambana, Christoforou	good	middle-aged	F	1.53m
01.05	Theatro, west slope	very good	middle-aged	F	1.53m
03.01	Theatro, west slope	moderate	young-aged	M?	
03.02	Theatro, west slope	good	young-aged	M	1.69m
03.03	Theatro, west slope	poor	adult	I	
03.04	Theatro, west slope	poor	adult	I	
03.05	Theatro, west slope	poor	adult	I	
03.06	Theatro, west slope	moderate	child (7y±24m)	I	
03.06	Theatro, west slope	poor	subadult	I	
07.01	Theatro, west slope	poor	subadult	I	
09.01	Theatro, west slope	very good	young-aged	F	1.62m

conjointly for adults and the results obtained from each method were combined. Age-at-death estimation for subadults was based on standards for dental eruption and development (Ubelaker 1989), measurement of long-bone diaphyseal length (Maresh 1970) and epiphyseal union (Scheuer & Black 2000). Based upon the overall estimation of available data, each individual was assigned to one of the following age categories: fetal (<birth), infants (birth–2.9 years), children (3–11.9 years), adolescents (12–19.9 years), young-aged adults (20–34.9 years), middle-aged adults (35–49.9 years) and old-aged adults (50+ years); age-at-death categories suggested in Buikstra and Ubelaker (1994: 9) are modified here in order not to overlap. Two additional categories are added in order to include subadults and adults for whom age-at-death remains unknown. Stature estimations used the length of complete femora according to equations for white males and females (Trotter 1970); no estimations were made for adults of unknown sex.

Skeletal examination of pathological lesions used standard data collecting methods for relatively complete skeletons as suggested by Buikstra and Ubelaker (1994: 107-123). The following lesions are the focus in this analysis: *cribra orbitalia*, porotic hyperostosis (frontal, parietal, and occipital bones), abnormal porosity and new bone formation on the cranial vault, periosteal new bone formation, skeletal trauma in the form of healed and unhealed fractured bones and *myositis ossificans*, and degenerative joint disease. Dental diseases (e.g., caries, linear enamel hypoplasia (LEH), calculus, antemortem tooth loss (AMTL), and alveolar resorption) were recorded following the criteria provided by Lukacs (1989: 265-271).

Skeletal lesions are inventoried by presence-absence and degree of severity. Calculations are made on the number of individuals affected by a pathological condition (crude prevalence rate) or the number of skeletal elements affected (true prevalence rate). Joint diseases of the appendicular skeleton are presented by joints (left and right) when at least one articular surface of the joint is preserved. Spinal diseases are presented by vertebral segments (cervical, thoracic, and lumbar). Expression and degree of severity of pathological conditions are described as in Buikstra and Ubelaker (1994: 112-123, Figs. 79a-112). Dental diseases are reported by teeth/sockets. The percentages reflect the observed (n) over the observable (N); no percentages are provided when N is lower than five.  $\chi^2$  is used to compare intra- and inter-site frequencies with statistical significance set at the  $p < 0.05$  level.

## Cranial deformation

In addition to the first case of cranial deformation previously published from the same site (Tritsaroli 2008, 2011), this paper includes a second individual with the same modification (skeleton 09.01 found in 2009). This individual was compared, like the first one 01.05, with two main types of cranial deformation that are commonly

adopted for classification: the anteroposterior type (AP) which includes the tabular forms (*tabula erecta* and *tabula obliqua*) of Dembo and Imbelloni (1938), and circumferential or circular type (C) which includes both Hrdlička's Aymara type (Hrdlička 1922) and the annular (*erecta* and *obliqua*) type (Dembo & Imbelloni 1938).

The analysis used the same methodology as for the first modified individual (Tritsaroli 2011) and incorporates all the adults of the sample. The crania were examined macroscopically and by using metric analysis and X-ray radiography: firstly, we recorded the abnormal concavities and convexities on the modified ectocranial bone surface; secondly, 15 measurements of more than five unmodified adult crania were analyzed (means and standard deviation) to compare heights, breadths, and arches; finally, modifications on diploic bone were verified by using radiographs. Radiographic analysis was conducted at the M.H. Wiener Laboratory for Archaeological Science, American School of Classical Studies at Athens (ASCSA).

## Results

### Demography and stature

The sample includes thirty-four adults and five subadults (Table 1). Middle-aged adults are the most numerous, followed by young-aged adults and an old-aged individual (Table 2). Females/probable females (N=12) outnumber males/probable males (N=9). Females are distributed in all age classes while males are young- and middle-aged. The average stature for twelve individuals is 1.63m (1.53–1.76m), that is 1.57m (1.53–1.62m) for females (N=6) and 1.70m (1.60–1.76m) for males (N=6).

Table 2. Demographic profile.

Age category		Indeterminate	Males	Females	Total
Fetal	(<birth)	0			0
Infants	(birth–2.9 years)	0			0
Children	(3–11.9 years)	2			2
Adolescents	(12–19.9 years)	1			1
Subadults	unknown	2			2
Young-aged adults	(20–34.9 years)	0	5	3	8
Middle-aged adults	(35–49.9 years)	1	4	5	10
Old-aged adults	(50+ years)	0	0	1	1
Adults	unknown	12	0	3	15
<b>Total</b>		<b>18</b>	<b>9</b>	<b>12</b>	<b>39</b>

## Dental diseases

The most common dental disease is calculus (27.6%), followed by periodontal disease (15.7%), AMTL (10.3%) and caries (9.2%) (Table 3). Maxillary teeth are more affected by caries and AMTL while mandibular teeth are more affected by calculus and periodontal disease. In particular, caries is observed on 11% of maxillary teeth (15/135) and 9.2% of mandibular teeth (19/233), calculus is observed on 17% of maxillary teeth (23/135) and 34% of mandibular teeth (78/231), AMTL affects 14% of maxillary sockets (18/129) and 12% of mandibular sockets (39/336), and periodontal disease affects 11% of maxillary sockets (20/189) and 19% of mandibular sockets (55/289). Carious lesions are mostly small (pit caries) and large (more than half of the crown destroyed); calculus is generally slight in size (Lukacs 1989: 265, 267).

**Table 3.** Dental diseases among adults (dental elements affected) with results of  $\chi^2$  statistical testing between males and females.

	Females			Males			$\chi^2$	p
	N	n	%	N	n	%		
Caries	181	29	16.0	123	2	1.6	16.57	0.00005
Calculus	179	53	29.6	123	41	33.3	0.47	0.490
AMTL	273	36	13.2	185	11	5.9	6.28	0.012
Periodontal disease	238	48	20.2	168	21	12.5	4.10	0.043

	Indeterminate			Total adults		
	N	n	%	N	n	%
Caries	64	3	4.7	368	34	9.2
Calculus	64	7	10.9	366	101	27.6
AMTL	97	10	10.3	555	57	10.3
Periodontal disease	72	6	8.3	478	75	15.7

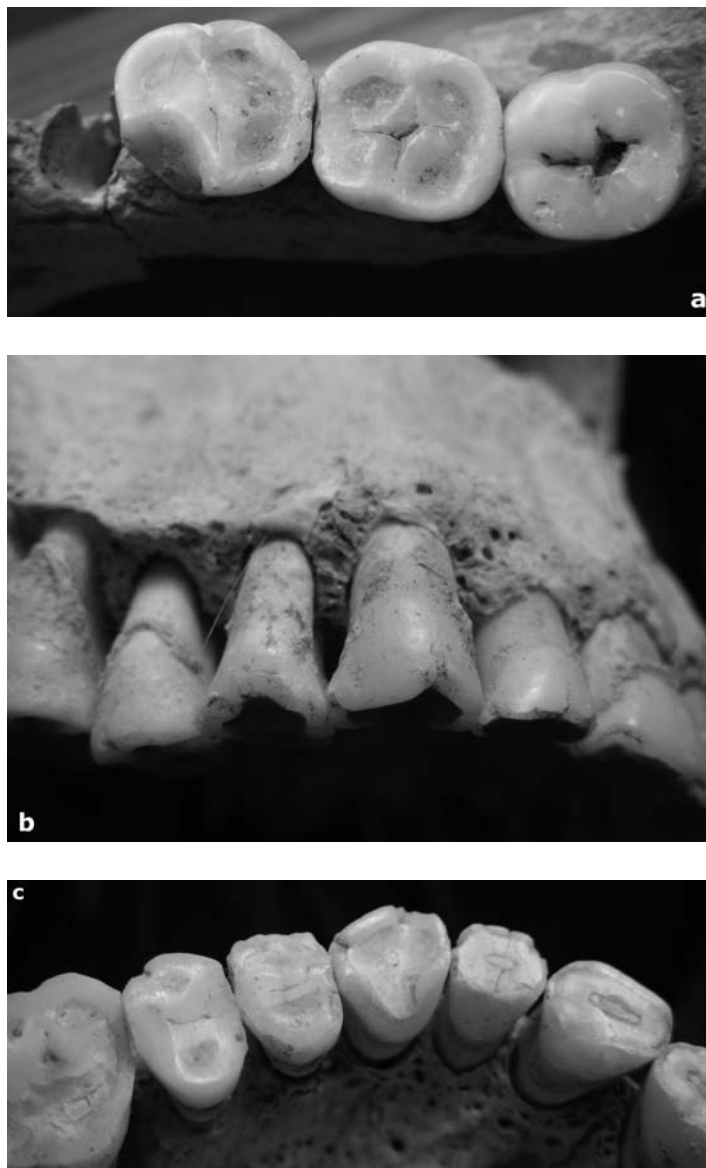
Absolute frequency rates for caries, AMTL and periodontal disease are significantly higher for females (16%, 13.2% and 20.2% respectively) than for males (1.6%, 5.9%, and 12.5% respectively) (Table 3). On the contrary, calculus shows higher rates among males (33.3%) than among females (29.6%). Subadults do not display dental lesions. In one case (young-aged female, Grave 2.A), porosity is present on the labial surface of the mandible, at the level of the right first molar, possibly secondary to oral infection and associated with periodontal disease.

## Dental trauma

Evidence of dental trauma is recorded on the dentition of two females. In the first case (Grave 2.B), the enamel of the dental crown of the right first mandibular molar is fractured. The edges of the remaining crown of the tooth have a smooth appearance due to wear during chewing after trauma; this feature differentiates this ante-mortem



fracture from post-mortem damage and shows that the fracture occurred sometime prior to death (**Figure 3a**). Dental wear for the rest of the dentition is normal and does not indicate an abrasive diet.



**Figure 3.** Dental trauma: (a) labial surface of right M<sub>1</sub> (Grave 2.B, adult probable female), (b) labial surface of right anterior maxillary teeth (Grave 05.01, middle-aged female), (c) occlusal surface of the same dentition.

A different pattern is observed on the dentition of the middle-aged female from Grave 01.05 (Figure 3b, c). Evidence of trauma is noted on the right side of the maxilla extending from the second incisor to the fourth premolar. These teeth have signs of chipping on the labial side of the crown and smoothing of the fractured edges suggesting continued wear of the broken surface after the fracture. The right lateral incisors and canine are worn abnormally on the lingual surface. In addition, the canine has a notch in the middle of the labial surface of the crown. No dentin exposure secondary to advanced wear is observed. The mandibular teeth do not show evidence of chipping but only moderate wear on the occlusal surface. The right temporomandibular joint shows osteophyte formation that is probably related to the unilateral dental trauma (1 of 8 individuals preserving the TMJ).

#### Dental and skeletal pathological indicators of stress and deprivation

The distribution of *cribra orbitalia* and porotic hyperostosis is presented in Table 4. One case of *cribra orbitalia* is noted in the old-aged female. The lesion is expressed by porosity with coalescence of foramina without thickening (degree score 3) and mixture of healing and active lesions at the time of death (activity score 3). This is associated with porosity on the external vault surface both adjacent to the sutures and near the frontal and parietal protuberances. Surface porosity for the adults is barely discernable or manifested by porosity only seen in small, circumscribed areas in the region of the parietal and the occipital bones, parallel to the sutures or near frontal bosses; no expansion of the diploë is observed. The lesion affects adults (males and females) and subadults, and is more frequent on the parietal and occipital than the frontal bones (Table 4).

**Table 4.** *Cribra orbitalia* (CO) and porotic hyperostosis (PH) (individuals affected).

	Females			Males			Indeterm.		Total adults			Subadults	
	N	n	%	N	n	%	N	n	N	n	%	N	n
CO	5	1	20.0	2	0	0.0	1	0	8	1	12.5	2	0
PH/frontal	11	2	18.2	6	3	50.0	3	0	21	5	23.8	3	1
PH/parietal	12	4	33.3	7	4	57.1	4	0	24	8	33.3	3	1
PH/occipital	12	4	33.3	7	4	57.1	4	0	24	8	33.3	3	1

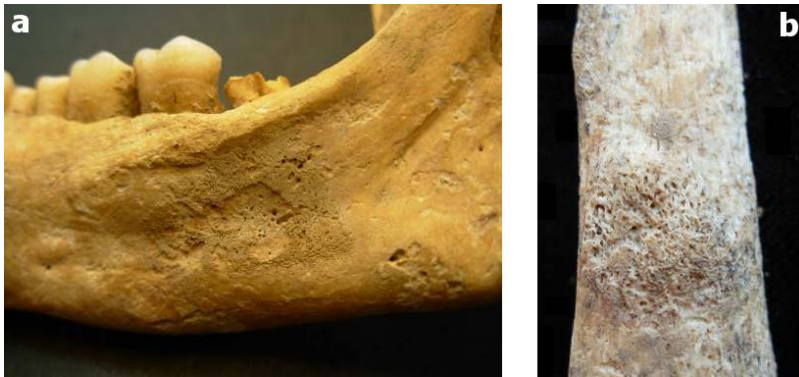
Multiple lesions occur on a 3–5 year-old child (Grave TII). The frontal bone displays new bone formation and porosity at the glabella. The mandible shows bilateral abnormal porosity on the coronoid process (medial surface); porosity is also evident on the mental eminence and around the mental foramina. The ectocranial surface of the right parietal bone presents fine porosity along the sagittal suture. The external surfaces of both temporal bones display localized fine porosity in the middle of the squama; endocranially, new bone formation and a mixture of fine and large pores are

noted on the anterior most region of the squama. The endocranial surface of the occipital bone shows fine porosity and new bone formation on the cruciform eminence, the internal occipital protuberance and parallel to the internal occipital crest. Fine porosity is also noted on the external surface of condylar parts of the occipital while the internal surfaces present large pores associated with vascular impressions at the region of the hypoglossal canal and the border of the foramen magnum. A mixture of fine and large pores cover almost the entire superior and inferior surfaces of the basilar part of the occipital bone. The left zygomatic bone exhibits fine porosity on the anterior surface. Finally, abnormal porosity with fine and large pores surrounds the foramen rotundum of the sphenoid bone (posterior view). Postcranial lesions include extensive abnormal porous bone along the diaphyseal surfaces of the humeri, radii and the left ulna. Irregular porosity is noted in the region of the ulnar tuberosity. As far as the partial preservation of this subadult skeleton allows, no bending deformities are observed for the long bones, sternal rib ends are not flattened, and no size changes are observed on vertebral bodies. A small preserved fragment of the left scapula is not affected. Os coxae and long-bone metaphyses are not preserved. No LEH is noted.

LEH is recorded for 9 of 25 adults (14.5% of teeth) and 1 of 3 subadults (7.3% of permanent teeth) (the 5–9 year-old child is included). No lesions are observed for the deciduous dentition. The lesion is more common among males (19.4% of teeth or 3 of 8 individuals) than among females (16.3% of teeth or 6 of 12 individuals). LEH is present on 17% (23 of 134 teeth) of maxillary teeth and 13% (29 of 225) of mandibular teeth. The observed differences are not statistically significant.

## Periosteal new bone

Periosteal new bone is manifested by woven bone deposits or lamellar bone without evidence of cloacae. Among adults, one case is noted for the young-aged female from Grave 09.01 with cranial deformation who has new bone formation on the right medial corpus surface of the mandible, inferior to the mylohyoid line; both woven and sclerotic reaction is evident (**Figure 4a**). Periosteal new bone is commonly attested for the appendicular skeleton and is more frequent for lower than for upper extremities; fibula (25%) and tibia (14.8%) are the most affected bones (**Table 5**). Three females are affected against one male. In a middle-aged female (Grave 1.B), two manifestations of periosteal new bone in the form of a porous thickened lesion with evidence of healing are noted on the distal half of the left radius (20×16mm on the palmar view and 15×9mm on the medial view) (**Figure 4b**). Among subadults, the upper extremities of the 3–5 year-old child from Grave TII are involved.



**Figure 4.** New bone formation (a) on the right medial view of the mandible inferior to the mylohyoid line; both woven and sclerotic reaction is evident (Grave 09.01, young-aged female), (b) in the form of a porous thickened lesion on the distal half of left radius, medial view (Grave 1.B, middle-aged female).

## Trauma

Traumatic conditions affect 5 of 34 adults; they are located on one clavicle (2.3% of bones or 1 of 24 individuals), eight ribs (9.5% of bones or 3 of 22 individuals), one ulna (2.2% of bones or 1 of 26 individuals), and one humerus (1.9% of bones or 1 of 29 individuals). Most cases (ribs and ulna) are present in females: a middle-aged adult (Grave II) has a fractured left clavicle; the middle-aged female with cranial modification has a fractured right ulna, two fractured left and three right ribs; the young-aged female with cranial deformation has one fractured right rib; finally, the middle-aged female from Grave 20 has two fractured left ribs. One case of *myositis ossificans* occurs on the distal humeral diaphysis (medial surface) of a young-aged male (Grave 03.02).

**Table 5.** Periosteal new bone (bones affected).

	Females			Males			Indeterminate			Total adults			Subadults		
	N	n	%	N	n	%	N	n	%	N	n	%	N	n	%
Humerus	24	0	0.0	18	0	0.0	12	0	0.0	60	2	3.3	6	2	33.3
Radius	23	1	4.3	15	0	0.0	8	0	0.0	52	3	5.8	6	2	33.3
Ulna	24	0	0.0	15	0	0.0	7	0	0.0	52	1	1.9	6	1	16.7
Femur	24	2	8.3	17	0	0.0	19	3	15.8	66	5	7.6	6	0	0.0
Tibia	22	4	18.2	11	2	18.2	15	2	13.3	54	8	14.8	6	0	0.0
Fibula	20	4	20.0	4	2		9	3	33.3	36	9	25	3	0	0.0

## Joint disease

Degenerative changes on the joints of the appendicular skeleton are found in all observed locations (**Table 6**). The most affected are the sternoclavicular (50%) and the hip joints (30.4%). The severity of the condition varies according to the anatomical location: marginal osteophytes, porosity and surface osteophytes are recorded for glenohumeral, sternoclavicular, acromioclavicular, elbow, hand and hip joints; marginal osteophytes and eburnation characterize the wrist, ankle and foot joints; marginal osteophytes, porosity and eburnation are observed on the knee joint.


**Table 6.** Degenerative joint disease (joints affected).

	Females			Males			Indeterminate			Total adults		
	N	n	%	N	n	%	N	n	%	N	n	%
Glenohumeral	20	5	25.0	14	1	7.1	5	1	20.0	39	7	17.9
Sternoclavicular	18	9	50.0	12	7	58.3	2	0		32	16	50.0
Acromioclavicular	13	5	38.5	11	0	0.0	1	0		25	5	20.0
Elbow	22	2	9.1	15	4	26.7	6	1	16.7	43	7	16.3
Wrist	19	2	10.5	10	0	0.0	3	1		32	3	9.4
Hand	21	3	14.3	12	1	8.3	7	0	0.0	40	4	10.0
Hip	22	8	36.4	16	3	18.8	8	3	37.5	46	14	30.4
Knee	19	4	21.1	12	1	8.3	9	3	33.3	40	8	20.0
Ankle	16	2	12.5	9	1	11.1	6	2	33.3	31	5	16.1
Foot	17	4	23.5	7	0	0.0	7	2	28.6	31	6	19.4

Vertebral osteoarthritis (OA) occurs on all spinal segments (**Table 7**). The condition is more frequent for the thoracic spine (65%), followed by the lumbar (50%) and cervical spine (47.6%). Vertebral OA is manifested either by a barely discernible or elevated ring of marginal osteophytes or syndesmophytes. The costal and articular facets are mostly affected by slight porosity and marginal osteophytes. In one case, the left articular facets between L4–L5 are polished with grooves; the lesion is possibly related to the L5 spondylolysis in the same individual (young-aged probable male from Grave V). One case of sacroiliac fusion (left side) occurs on a young-aged male (Grave 03.02) (**Figure 5**); Schmorl's nodes (**Table 7**) affect the thoracic (30%) and/or lumbar (20%) spine of six adults; the lesion is barely discernible or of moderate expression in four individuals and more pronounced in two individuals.

## Congenital abnormalities

Several congenital abnormalities involve the spine and the foot. Sacralization of L5 (**Figure 6**) affects the spine of three males (16.7% or 3 of 18 L5+sacra observed). The assimilation of L5 into the sacrum varies in expression: it is complete in two individuals and incomplete in the third one. A single block vertebra involving T3–T4 (1 of 20 thoracic vertebral segments) is observed on the young-aged female (Grave I)




**Figure 5.** Unilateral (left) sacroiliac coalition (Grave 03.02, young-aged male).

and results in a single spinous process and vertebral body; it is not accompanied by other spinal or extra-spinal disturbances. Bilateral spondylolysis affects the lower back (1 of 20 lumbar segments) and it is recorded on L5 of a young-aged probable male (Grave V). Finally, bilateral symphalangism in the distal interproximal joint of the fifth toe occurs on the middle-aged female (Grave 01.05) (5.6% or 1 of 18 individuals). The aforementioned conditions do not conjointly affect the same individual.

**Table 7.** Vertebral osteoarthritis (OA) and Schmorl's nodes (vertebral segments affected). CV – cervical vertebrae, TV – thoracic vertebrae, LV – lumbar vertebrae, SN – Schmorl's nodes.

	Females			Males			Indet.		Total adults		
	N	n	%	N	n	%	N	n	N	n	%
CV OA	10	6	60.0	8	3	37.5	3	1	21	10	47.6
TV OA	10	7	70.0	8	6	75.0	2	0	20	13	65.0
LV OA	11	5	45.5	8	5	62.5	1	0	20	10	50.0
CV SN	10	0	0.0	8	0	0.0	2	0	20	0	0.0
TV SN	10	2	20.0	8	4	50.0	2	0	20	6	30.0
LV SN	11	2	18.2	8	2	25.0	1	0	20	4	20.0
TV/ribs OA	10	6	60.0	8	4	50.0	2	0	20	10	50.0




**Figure 6.** Sacralization of L5 (Grave without number, middle-aged male).

### Tumor of cartilaginous origin

One case of solitary cartilaginous exostosis (osteochondroma) is noted on the proximal metaphysis of the left tibia (Grave without number, middle-aged male) (**Figure 7**). The exostosis is pedunculated and pointed inferiorly.

### Cranial modification

Cranium 09.01 shows a concavity in the middle of the frontal bone associated with a postcoronal transverse groove and a concavity at lambda (**Figure 8a**). The bone is convex and elevated at the bregma and the prebregmatic region. These features are also observed on the sagittal section of the cranium by radiography (**Figure 8b**): the diploë is underdeveloped in the frontal and prebregmatic regions as well as at lambda where pressure has been applied, resulting in an undulation of diploic bone. In frontal view,



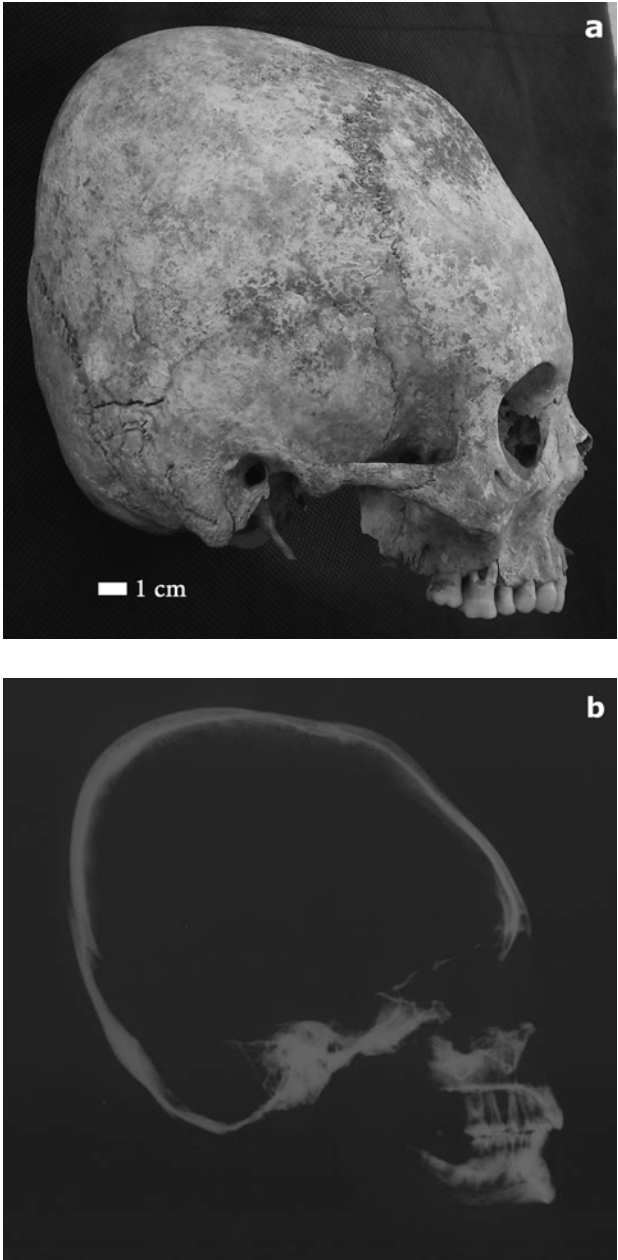
**Figure 7.** Ossification of cartilaginous cap of a pedunculated osteochondroma of the proximal tibia, left side (Grave without number, middle-aged male).

the cranium is swollen symmetrically at the region of the squamosal suture. Furthermore, bilateral concavity, which has been caused probably by the pressure of small, cylindrical or rounded objects, is observed on frontal bones (at the region of frontal bosses). The orbits are very deep and the interorbital region has become very wide. No modifications are observed on the mandible. The observed alterations of shape resemble those recorded for individual 01.05 previously studied (Tritsaroli 2011).

Metric analysis (Table 8) shows that the differences between the modified cranium and the rest of the adults are mainly located on the vault. Porion-bregma height and maximum cranial breadth are lower for the modified cranium while bi-auricular breadth is higher. Parietal arc and foramen magnum length are lower only for cranium 01.05. Modification is more pronounced for cranium 01.05 than for cranium 09.01.

The bunning at the nuchal area (01.05) and lambda (09.01) is suggestive of artificial modification, while the shape of the frontal bone is a type of distortion that can only be achieved by manipulation with pressure, which causes the frontal bone to recede posteriorly at an increased rate (Schendel et al. 1980). The superior most portions of the occipital (01.05) and parietal bones (both crania) extend posterosuperiorly resulting in a long loaf-like appearance in superior view (Antón 1989; Dingwall 1931). These features clearly describe intentional, annular modification, and suggest that the method used to achieve this particular cranial shape is by means of bandages. In the second case, a small rounded object was probably symmetrically applied on the frontal bones. The post-coronal transverse groove also suggests bandage marks. In summary, evidence obtained by metric analysis is consistent with visual observations





**Figure 8.** Modified skull 09.01: (a) right lateral view of the cranium and (b) right lateral radiography of the skull (50kV, 0.15mA, 90cm, 0.25sec).

and radiography and shows morphological changes mainly on the cranial vault, but also on the base and face. A single or double bandage was probably applied, running over to the point of the occipital squamous (01.05) or lambda (09.01), then up to the frontal bone and the postcoronal region, with (09.01) or without (01.05) the pressure by hard objects.

## Discussion

### Health and disease

The city of Maroneia is known for being prosperous throughout Antiquity until the Early Byzantine period. Maroneia experienced continuous occupation and progress that can be easily attributed to its strategic location at a crossroad between the Balkans and the East. Furthermore, the survival of the city through invasions and conflicts with migrating groups is due in large part to the ability of its inhabitants to adapt to changes imposed upon them thus creating a multicultural society (Tritsaroli 2011).

**Table 8.** Measurements (in mm), means and standard deviations (SD) for the modified (01.05 and 09.01) and the unmodified crania. The left side is included for pair measurements (after Martin & Saller 1957). BBH – basion-bregma height, MFB – maximum frontal breadth, FML – foramen magnum length, BAB – biauricular breadth, PBH – porion-bregma height, MCB – maximum cranial breadth, SPA – sagittal parietal arc, SOA – sagittal occipital arc, MH – mastoid height.

Cranium	Sex	BBH	MFB	FML	BAB	PBH	MCB	SPA	SOA	MH
Modified cr. 01.05	F	144	116	30	116	136	126	113	113	37
Modified cr. 09.01	F	140	116	35	116	131	128	135	114	32
Stogiannidou K1	F								103	31
Kambana, Th. 1/94	F?						133	130	100	
Christoforou 20	F	136		31	116	127		111	113	33
Christoforou 1B	F						128	129		32
Kambana, Teatro I	F	131	117	34	118	122	134	135	119	31
Kambana, Teatro III	F									29
Kambana, no number	F	138	113	33	113	125	137	143	109	33
Christoforou 16	F?								98	34
Stogiannidou TI	M								111	
Theatro 03.02	M	145	122	35	128	137	137	126	114	35
Christoforou 5	M	144	112		118	135	134	138	115	33
Christoforou 10	M								121	43
Kambana, no number	M?		122		121	120	136	128		
Kambana, Teatro V	M?									36
Kambana, no number	I									36
Kambana, Teatro II	I			36					115	34
Kambana, Th. 1/88	I									30
N (unmodified crania)		5	5	5	6	6	7	8	11	14
Mean		138.8	117.2	33.8	119	127.7	134.1	130	110.7	33.6
SD		5.8	4.8	1.9	5.1	6.9	3.1	9.6	7.5	3.4

Some short periods of famine are also reported for the region of Thrace in textual sources (see Stathakopoulos 2004: 204-205, 265). The sample from Maroneia consists of only 39 individuals and for this reason it cannot be representative of the living population from which it came; as far as the limited sample can indicate, these individuals have low or moderate frequencies of dental and skeletal indicators of growth retardation and physiological stress; joint diseases affect almost half of the adults while trauma is present in few cases.

The highest rates of dental diseases in the Maroneia sample are noted for calculus. Several causative factors of calculus formation should be considered when studying skeletal assemblages (e.g., individual susceptibility, food preparation methods, poor oral hygiene, drinking water mineral content, oral microorganisms) (Lieverse 1999). In archaeological skeletal series, an alkaline oral environment suggestive of protein-rich diet (Lillie 1996) and poor dental hygiene is considered to be responsible for the amount of this lesion. Antemortem tooth loss can be the result of variations in dietary consistency, nutritional deficiency diseases, cultural or ritual ablation and trauma (Lukacs 1989, 2007). Consumption of fermentable sugars, especially when refined or when contained in sticky food, leads to a marked increase in the prevalence and intensity of carious lesions (Hillson 1986; Larsen 2015; Larsen et al. 1991; Touger-Decker & van Loveren 2003) that would be an important factor in periodontal disease and conducive to alveolar resorption and tooth loss (Hillson 1979). At Maroneia, the high frequency of calculus in contrast to that of caries, AMTL and periodontal disease suggests that these people as a whole did not consume a soft, high-carbohydrate staple diet. On the contrary, they must have had an adequate diet comprising the consumption of animal proteins (e.g., dairy products). This hypothesis agrees with results obtained from stable isotope analysis on Greek Byzantine populations according to which Byzantine diet was primarily based on C3 staples (wheat and barley) and domesticated animals that fed on C3 plants along with substantial consumption of meat or dairy products. In addition, the consumption of significant amounts of marine proteins by some Byzantine populations should be related to the impact of dietary restrictions and fasting regulations of the Orthodox Church mainly including the prohibition of meat consumption (Bourbou et al. 2011).

When dental diseases are examined conjointly, calculus absolute frequency rate is higher for males while caries, AMTL and periodontal diseases are more common among females; the difference in caries frequency between females and males is particularly striking. Various cultural factors such as differential access to foodstuff and consumption, different dietary habits for males and females, or even religious regulations for women in early Christian tradition (Grimm 1995) could have influenced diet and oral health status. In general, the consumption of specific foods, especially meat, during fasting was prohibited for nearly half of the year. Written sources (Jerome, 345-

420 AD) attest that women were encouraged to adopt a restricted diet and avoid wine consumption by integrating mainly vegetables, wheat bread and occasionally fish into their diet. However, only through the analysis of human remains can it be revealed to what extent average people adopted a fixed regime in everyday life; bioarchaeological studies of Byzantine samples from Crete showed that dental pathologies affect more males than females but stable isotope analysis revealed no differential access to foodstuff by sex (Bourbou 2010: 152). The sample of Maroneia is too small to draw general assumptions; the analysis of larger samples from the region of Thrace and the application of biochemical methods should investigate possible gender-related variations in diet and consumption. Finally, the cases of dental trauma on the women of Maroneia could be attributed either to accidental biting on hard materials that caused the fracture of the crown (Grave 2.B) or to extramasticatory activities (Grave 01.05); in the second case, the occupational dental abrasion recorded unilaterally on anterior maxillary teeth co-occurs with temporomandibular joint osteoarthritis and points to a high masticatory load although the exact activity remains unknown.

*Cribra orbitalia* and porotic hyperostosis are usually associated with some types of anemia either of genetic origin or from acquired conditions such as anemia-related nutritional deficiencies and subsequent chronic deprivation (e.g., chronic dietary deficiencies and malabsorption of vitamin B<sub>12</sub> or folic acid, scurvy, rickets), infections, parasitic load and other chronic stressors that influence iron metabolism, or any combination of the causes mentioned above (Stuart-Macadam 1985; Walker et al. 2009). In the adults of Maroneia, both types of lesions are of moderate expression and they usually show healing. There are no pathological lesions suggestive of genetic anemia on the postcranial bones. On the other hand, signs of growth arrest on teeth (LEH) provide a reliable indicator of periods of stress during tooth crown development caused by childhood disease, vitamin deficiency, malnutrition or infection (Goodman & Rose 1990, 1991) and therefore they are important factors in elucidating living conditions. While keeping in mind the limitations imposed by the small sample size, we observe that LEH was recorded on individuals from all age groups and both sexes who were probably the survivors of a stress episode during their early years.

Periosteal new bone formation occurs in response to any pathological stimulus and accompanies a variety of disease processes including inflammation, specific and non-specific infections, metabolic diseases and infection secondary to trauma (Mensforth et al. 1978; Ortner 2003; Weston 2012). In archaeological collections, the tibial diaphysis is one of the most common sites of periosteal new bone formation; the anterior and lateral aspects of the tibia are not surrounded by a large amount of soft tissue and for this reason they have cooler temperatures making them more susceptible to infections (Ortner 2003: 209). In addition, the anatomical location more readily exposes the anterior tibial surface to trauma against which little protec-

tion is offered by soft tissue and overlying muscle (Ortner 2003: 209; Larsen 2015: 89). In Maroneia, periosteal new bone appears especially on the shaft of tibiae and fibulae of adults. The morphology and location of the lesion for a small part of this population suggests that non-specific deprivation or minor injury should have been caused from ordinary, daily activities easily found in an Early Byzantine urban, quite safe, environment rather than to a dietary deficiency or other disease complexes.

Identifying dry-bone manifestations of malnutrition for children and attributing them to a specific pathological feature is an exigent issue in paleopathology (Ortner & Mays 1998; Ortner et al. 1999, 2001). Diseases such as scurvy, rickets and iron-deficiency anemia, which are related to undernutrition, can produce similar pathological lesions on cranial bones and these conditions may co-occur in a single skeleton in any combination (Ortner et al. 1999, 2001). The resemblance of lesions often makes differential diagnosis a difficult task that largely depends upon the time during which the disease affected the individual as well as skeletal preservation and completeness. However, specific dry-bone manifestations on the cranial and post-cranial skeleton could lead to a differential diagnosis: for example marrow hyperplasia of the skull and evidence of enlarged diploë occur in anemia (Brickley & Ives 2006; Ortner et al. 1999, 2001), abnormal porous lesions on at least one of the greater wings of the sphenoid and abnormal porosity in the scapulae are suggestive of scurvy (Ortner et al. 1999, 2001), and flared sternal rib ends, bowing, thickening, and abnormal angulation of distal metaphysis on long bones are considered among other criteria for the diagnosis of rickets (Mays et al. 2006; Ortner & Mays 1998).

The 3–5 year-old child (Grave TII) examined here exhibits multiple lesions on the cranial and post-cranial skeleton that can be seen as expression of deprivation including undernutrition. However, the paleopathological profile of this child does not correspond to a recommended range of skeletal manifestations in immature remains associated with a particular nutritional deficiency (Ortner et al. 2001; Brickley & Ives 2008); at the same time, attributing a particular pathological feature to a specific disease is problematic due to the partial preservation of the skeleton. Recent studies on skeletal samples from Greece suggest that the development of subadult scurvy during the Byzantine period may have been associated with the onset of weaning at 3–4 years as metabolic diseases tend to develop during this critical period of children's lives (Bourbou 2014); the child examined here falls within this age range. It is possible that this individual underwent episodes of stress although the exact causes cannot be specified; it is also important to underline that this unique case in the small subadult sample of Maroneia cannot be suggestive of impoverished environmental circumstances for the sample as a whole.

The anatomical locations of OA and injuries, especially on the upper extremities, the back and the thorax, point to repetitive stress and minor trauma as the most

plausible explanation for these lesions. Schmorl's nodes are habitually appreciated as activity induced and most commonly associated with great stress on the spine (Waldron 2009: 45) although recent studies have shown a correlation between vertebral morphology and the presence of disc herniation in the lower thoracic and lumbar spine (Plomp et al. 2012, 2015). Sacroiliac fusion can be recorded as a developmental defect or as a diagnostic criterion for joint diseases. With respect to epidemiology, sacroiliac fusion is more common in males (like in Maroneia) than in females and occurs more frequently in the elderly (Resnick et al. 1975). Differential diagnosis (Barnes 2012) shows that the lesion examined here cannot be identified as a developmental defect. Sacroiliac fusion also occurs in several paleopathological conditions (e.g. spondyloarthropathy, gout or DISH) (Ortner 2003; Rothschild 2015; Waldron 2009; Waldron & Rogers 1990); however, the case from Maroneia is isolated and no specific diagnosis can be made.

Congenital abnormalities are caused by problems during the fetus development before birth. Their etiology is not well understood; some birth defects are inherited, others are caused by harmful environmental factors during pregnancy that affect the baby, and others are multifactorial, resulting from a complex combination of genetic and environmental influences. Among congenital deformities found in this assemblage, sacralization is the most frequently observed and occurs on three males. Sacralization is the defect in which L5 vertebra is incorporated into the sacrum, when shifting occurs on the superior part of the lumbosacral border and the lumbar spine loses a segment (Aufderheide & Rodríguez-Martín 1998; Barnes 1994, 2012). Symptoms include severe lower back pain radiating from the sacral area and down the leg; this condition can cause curvature and rotation of the lumbar spine and lead to progressive scoliosis.

A male individual displays spondylolysis. The term describes the ossification union failure of the pars interarticularis of the vertebra resulting in separation of the vertebra into the ventral part and the dorsal part (Aufderheide & Rodríguez-Martín, 1998). The etiology can be congenital and traumatic associated with unusual stress in the lower back (Merbs 1983). These two causes are complementary since one individual can be congenitally predisposed to a stress fracture of the pars interarticularis.

The young-aged female of the sample has a single block vertebra; this abnormality forms when adjacent vertebral segments fail to separate when the fissure between precursor developing units of resegmented sclerotome does not appear (Barnes 2012). Single block vertebra is usually not pathological; the joined vertebral segments maintain integrity with the same dimensional separation expected for the disk space between separated vertebral segments (Barnes 2012). This case should not be confused with Klippel-Feil syndrome that is characterized by the fusion of several cervical vertebrae affected by ventral hypoplasia, with or without upper thoracic involvement

(Barnes 1994, 2012). Single block vertebra appears to be a familial trait and occurs mainly in the cervical but also in the thoracic segment.

Finally, pedal symphalangism is a congenital trait that refers to the absence of the joint between the intermediate and distal phalanges of the lesser toes (Barnes 2012; Case & Heilman 2005). In modern populations, pedal symphalangism is very common varying between 35% and 80% (Case & Heilman 2005). This trait is considered to be of great importance to bioarchaeological studies in assessing biological distance since it is presumed to be inherited (Case & Heilman 2005). In Maroneia, this trait occurs on a middle-aged woman; differential diagnosis excludes trauma (no flexion, rotation nor deviation is observed).

In summary, various factors (e.g., immune response, diet, heredity, health care) play an important role as to whether an individual becomes more resistant and lives or more vulnerable and dies. It is also noteworthy that in archaeological populations the susceptibility of an individual to disease and death remains largely unknown (Wood et al. 1992). Based on dental and skeletal evidence, the overall health pattern at Maroneia does not show a deficient diet or important physiological stress; on the contrary, these individuals should have had a small risk of exposure to hazards and infectious agents, and probably sufficient resistance to disease to survive long enough for it to affect the skeleton. The number of congenital abnormalities recorded for such a small sample raises questions about the genetic background and kinship of these individuals and should be further investigated.

### Comparison to other Early Byzantine samples from Greece

For the purposes of the present analysis, several studies are considered including the sites of Eleutherna and Messene (Bourbou 2003, 2004), Sourtara (Bourbou & Tsilipakou 2009), Nemea (Beatrice 2012), Akraiphnio (Tritsaroli 2017), Aliko (Buchet 1986; Buchet & Sodini 1984), Knossos (Musgrave 1976) and Corinth (Wesolowsky 1973). As far as dental and skeletal paleopathological conditions are concerned, comparable data were available for the sites of Sourtara (northern Greece), Akraiphnio (Boeotia), Nemea and Messene (Peloponnese) and Eleutherna (Crete). This attempt helps to contextualize lifestyles from Maroneia within a wider regional framework during the Early Byzantine period.

The demographic profile for the adults of Maroneia does not differ considerably from the other Early Byzantine samples. Subadults are underrepresented when compared to all Early Byzantine series, and females outnumber males in Maroneia and Knossos (**Table 9**). The average stature of the adults of Maroneia is comparable to the values obtained for Early Byzantine series and other past Greek populations (Angel 1984).

With respect to dental diseases, caries and calculus frequencies are significantly higher compared to Akraiphnio, Sourtara, Messene, and Eleutherna. On the contrary, the inhabitants of Maroneia are significantly less affected by AMTL than the inhabitants of Akraiphnio, Sourtara and Eleutherna. It is noteworthy that the distribution of dental caries, calculus and AMTL observed at Maroneia is opposite to that of Sourtara for which dental data suggest a dependence on carbohydrates in the diet (Bourbou & Tsilipakou 2009).

Low to moderate frequencies of *cribra orbitalia* and porotic hyperostosis are generally recorded for Early Byzantine series, except the high percentages of the former displayed by the inhabitants of Nemea (29.5%). On the contrary, the occurrence of LEH for Maroneia (14%) is among the highest (along with Akraiphnio and Nemea) observed for Early Byzantine collections. As far as inflammations of the periosteum are concerned, the highest prevalence rates are noted for the people of Nemea where tibial periosteal reactions reach 86.9% for adults and 47.3% for subadults (Beatrice 2012). The occurrence of new bone formation at Maroneia does not exceed 15% (for both adults and subadults), it resembles that obtained for Akraiphnio (16.2%) but is higher to that obtained for the samples of Sourtara, Eleutherna and Messene that reaches 7% for all sites (Bourbou 2006).

With respect to joint diseases of the appendicular skeleton, the samples of Maroneia and Akraiphnio have generally higher frequencies compared to the samples of Eleutherna, Sourtara, Messene and Nemea. Vertebral OA is comparable among Early Byzantine sites. The frequency of Schmorl's nodes at Maroneia (20-30%) is among the lowest compared to other Early Byzantine sites: 25-75% at Sourtara, 41-59.3% at Eleutherna, 36-34.2% at Messene, and 10-30.4% at Akraiphnio.

A small number of fractures is reported among different Early Byzantine sites involving mainly the upper and lower extremities, and the spine. The cases recorded at Maroneia are slightly more frequent compared to other Early Byzantine samples. At

**Table 9.** Comparative data on Early Byzantine human skeletal series from Greece (stature is reported as in the original publications, either as average or range). M – males, F – females, Ad. – adults, Sub. – subadults.

Site	Number of individuals				Stature	
	M	F	Ad.	Sub.	M	F
Maroneia (this paper)	9	12	34	5	1.70	1.57
Akraiphnio (Tritsaroli 2017)	5	2	27	18	1.73	1.78
Nemea (Beatrice 2012)	41	36	79	34		
Thassos (Buchet 1986; Buchet & Sodini 1984)	22	1	23	124	1.62	1.50
Sourtara (Bourbou & Tsilipakou 2009)	27	15	56	15	1.70	1.52
Messene (Bourbou 2003, 2004)	23	12	55	19	1.70	1.52
Lerna (Wesolowsky 1973)	54	43	117	47	1.63-1.73	1.60
Eleutherna (Bourbou 2003, 2004)	52	21	100	51	1.69	1.60
Knossos (Musgrave 1976)	9	12	30	20	1.61-1.78	1.50-1.62



Nemea most traumatic lesions are recorded on males and they involve the skull as well as clavicle and lower limbs; traumatic lesions at Maroneia affect mainly the women's upper extremities and thorax. Finally, the Maroneian skeletons present several cases of developmental defects (sacralization, single block vertebra, lumbar spondylolysis and pedal symphalangism) thus resembling the assemblage from Akraiphnio; however, none of these defects co-occurred in the same individual. Few cases are observed at Sourtara (lumbar cleft neural arch), Messene, and Eleutherna (neural arch defect on the sacrum).

In summary, results obtained for the assemblage of Maroneia are comparable to contemporary skeletal series from Greece. While always keeping in mind the limitations imposed by the variable sizes of the samples, it seems that Early Byzantine collections have a similar demographic profile. The under-representation of subadults in Maroneia is probably due to the partial excavation of the cemetery outside the city walls. Although interobserver divergence in scoring the presence of lesions must be taken into account, the prevalence rates of dental and skeletal paleopathological conditions show inter-site variations in the patterns of physiological and activity stress related indicators which could be the result of variable socioeconomic contexts from which the samples came; furthermore, prevalence rates of paleopathological conditions were higher for males than for females (all samples considered) probably suggesting differences in lifestyles but also physiological wear and tear of joints due to advanced age. In terms of frequency and severity of lesions, individuals from Maroneia are placed at a medium level when compared to other sites from Greece. Obviously, larger samples need to be studied in order to evaluate the biological status of individuals from urban centers in comparison to the countryside.

## Cranial modification and cultural contact

An extended overview of the anthropological record of cranial modification in Greece and the Balkans, on practices regarding childcare in Byzantium as well as burials of foreigners in Christian burial grounds is provided in a previous analysis (Tritsaroli 2011). This information can be summarized as follows. Firstly, cranial deformation in Byzantine Greece did not arise in isolation from the surrounding regions and it is associated with the migration period during the 1<sup>st</sup>–9<sup>th</sup> c. AD (Fóthi 2000). Various cases close to Greece are reported in Romania, Bulgaria, former Yugoslavia, Hungary, and Italy (Kiszely 1978; Molnár et al. 2014). Several population groups such as the Alans, Avars, Quades, Goths, Gepids, and Huns had adopted this practice. Secondly, several cases of cranial deformation are reported from Greece including examples from the Athenian Agora (Lorentz 2009) and an Early Ottoman cemetery at Ancient Corinth (Rohn et al. 2009). Thirdly, where circular cranial modification is concerned, some contemporary cases are found in Hungary (Kustár 1999; Marcsik &

Pap 2000), Italy (Saponetti et al. 2005), and Bulgaria (Enchev et al. 2010). Fourthly, the Huns are known for having frequently practiced a pronounced form of circular modification and for spreading this type throughout the Eurasian steppes after 200 AD (Molnar et al. 2014, Torres-Rouff & Yablonsky 2005). Subjugated groups assimilated into Hun culture also practiced artificial cranial modification.

A closer insight into the relationships between the Byzantine Empire and the Huns during the 5<sup>th</sup> c. AD shows that culture contact emerged between them at some frontier zones of Northern Greece including Thrace. Furthermore, historical sources testify about the devastating invasion of Attila into Thrace in the middle of the 5<sup>th</sup> c. AD. According to these data, the circular type of headshaping displayed by the two females, whose burials date to the 5<sup>th</sup>–6<sup>th</sup> c. AD, coincides with or may slightly post-date the presence of the Huns in northern Greece, especially at the city of Maroneia; the cases of circular vault modification, therefore, are most likely linked to Hun tradition (Tritsaroli 2011). Finally, sociocultural practices related to the care of newborn babies and children in Byzantium are very different from what needs to be practiced in order to produce a permanent, intentional modification of the cranium. Consequently, it seems unlikely that the Byzantine Greeks practiced cranial modification. On the contrary, this practice probably indicates the presence of individuals with a different culture rather than the adoption of the practice itself by the Byzantines of Maroneia.

In addition to the circular cranial modification, paleopathological features taken together appear to distinguish headshaped women from the rest of the sample, particularly other females. Both individuals present multiple, healed rib fractures that are probably due to accidents, falls, or direct blows to the chest, while the older one has an injury near the wrist that may have resulted from a fall (Lovell 1997). Furthermore, the older female exhibits extensive trauma on the right side of the dentition revealing nonmasticatory functions. Contrary to other women of the sample, it seems that these females had customs linked to a different culture, and have adopted a way of life with higher risk of trauma.

## Conclusions

This paper analyzes human skeletal remains from the Early Byzantine city of Maroneia in Thrace. Health status, as measured by physiological and activity related stress indicators, appears normal and broadly similar to those from other rural and urban sites in Greece and does not show deteriorating living conditions caused by major social and geopolitical transformations or natural disasters. On the contrary, it is probable that these people enjoyed prosperity; they lived a pleasant and comfortable life and they had a quite good nutrition. The skeletal evidence agrees with historical and archaeological evidence according to which Maroneia was prosperous for many centuries.

This estimation is in agreement with recent intensive archaeological survey data from other regions of Greece suggesting that besides the general instability that characterizes these centuries in many aspects (e.g., demography, economy, politics) alternative explanations are possible (e.g., the Late Antique paradox) according to which several signs of development, prosperity and flourishing activity are also present (Bintliff 2014). Always bearing in mind the small sample size, several differences observed between sexes (e.g., dental diseases and oral health) should be treated with caution and must not be interpreted as indicative of distinct gender roles and relationships. The occurrence of several congenital abnormalities within such a small sample is interesting but not conclusive and could be used in future research in order to investigate kinship and migration.

The population of the Byzantine Empire was highly diverse and various groups were distinguished by their origin, language, religious beliefs, and customs (Lefort 2006). However, historical sources indicate that people from different religions and ethnicities were not always in conflict with each other, but peacefully coexisted within the generally Orthodox, Christian society (Tritsaroli 2011). Consequently, much of our understanding of Byzantine population is closely tied to continuous interactions between groups with different cultural backgrounds. Intentional cranial modification represents an additional source of information about cultural diffusion and regional interplay by the spread of different practices in the Greek territory during the Early Byzantine period. This was not a customary practice in Christian and Byzantine tradition and culture. However, the Huns practiced a pronounced form of circular modification. Consequently, these two specimens strongly support the hypothesis that a larger group linked to the Huns lived in the city and was integrated into this Early Byzantine society (Tritsaroli 2011).

The fact that both individuals were females leads this hypothesis a little further. Bearing in mind the small sample size and the rarity of this practice for the region and period in question, these individuals raise questions about the differential adoption of cranial modification by women. Were these women installed away from their homelands and did they need to maintain a particular physical identity of a larger contemporary population, or were they descendants of a recently eclipsed group wishing to bare a distinctive mark of their cultural heritage? Larger samples from the region of Thrace must be studied and future biogeochemical analysis needs to be undertaken in order to explore the origins of the individuals buried in the cemetery and investigate residential mobility and migration. In any case, headshaping reflects the biocultural diversity of the society of Maroneia and illustrates, to some extent, the sociocultural changes that took place during the Byzantine era in Greece.

## Acknowledgements

The study of human skeletal remains from Maroneia was possible through the funding of the Malcolm H. Wiener Laboratory for Archaeological Science, ASCSA. The first author wishes to thank Sherry Fox, former director of the Wiener Laboratory, for her advice during this project. The authors thank the editor and the reviewers of this paper for providing useful advice and suggestions that considerably improved the original text; the first author is grateful to P. Nick Kardulias for his in-depth comments.

## References

- Angel J.L. (1984), *Health as a crucial factor in the changes from hunting to developed farming in the eastern Mediterranean* [in:] “Paleopathology at the origins of agriculture”, M.N. Cohen, G.J. Armelagos (eds.), Orlando: Academic Press, pp. 51-73.
- Antón S.C. (1989), *Intentional cranial vault deformation and induced changes of the cranial base and face*, *American Journal of Physical Anthropology* 79:253-267.
- Aufderheide A., Rodríguez-Martín C. (1998), *The Cambridge encyclopedia of human paleopathology*, Cambridge: Cambridge University Press.
- Barnes E. (1994), *Developmental defects of the axial skeleton in paleopathology*, Niwot: University of Colorado Press.
- Barnes E. (2012), *Atlas of developmental field anomalies of the human skeleton: A paleopathology perspective*, Hoboken: John Wiley & Sons, Inc.
- Beatrice J.S. (2012), *Community health at Nemea, Greece: A bioarchaeological approach to the impact of sociopolitical change in Byzantium*, unpublished PhD thesis, Michigan State University.
- Bintliff J.L. (2014), *Prosperity, sustainability, and poverty in the Late Antique World: Mediterranean case studies* [in:] “Production and prosperity in the Theodosian Period”, I. Jacobs (ed.), Leuven: Peeters, pp. 319-326.
- Bourbou C. (2003), *Health patterns of Proto-Byzantine populations (6<sup>th</sup>–7<sup>th</sup> centuries AD) in South Greece: The cases of Eleutherna (Crete) and Messene (Peloponnese)*, *International Journal of Osteoarchaeology* 13:303-313.
- Bourbou C. (2004), *The people of Early Byzantine Eleutherna and Messene (6<sup>th</sup>–7<sup>th</sup> centuries A.D.). A bioarchaeological approach*, Athens: University of Crete.
- Bourbou C. (2006), *Infectious conditions observed on Greek Proto-Byzantine (6<sup>th</sup>–7<sup>th</sup> centuries A.D.) and Middle-Byzantine (11<sup>th</sup> century A.D.) skeletal series* [in:] “La paléodémographie. Mémoire d’os, mémoire d’hommes. Actes des 8<sup>èmes</sup> Journées Anthropologiques de Valbonne”, L. Buchet, C. Dauphin, I. Séguéy (ed.), Antibes: Editions APDCA, pp. 85-99.
- Bourbou C. (2010), *Health and disease in Byzantine Crete (7<sup>th</sup>–12<sup>th</sup> centuries AD)*, Burlington, VT: Ashgate Publishing.

- Bourbou C. (2014), *Evidence of childhood scurvy in a Middle Byzantine Greek population from Crete, Greece (11<sup>th</sup>–12<sup>th</sup> centuries A.D.)*, International Journal of Paleopathology 5:86-94.
- Bourbou C., Tsilipakou A. (2009), *Investigating the human past of Greece during the 6<sup>th</sup>–7<sup>th</sup> centuries A.D. Patterns of life and death at the site of Sourtara Galaniou Kozanis in Northern Greece* [in:] “New directions in the skeletal biology of Greece”, L. Schepartz, S. Fox, C. Bourbou (eds.), Hesperia Supplement 43, Princeton: American School of Classical Studies at Athens, pp. 121-136.
- Bourbou C., Fuller B.T., Garvie-Lok S.J., Richards M.P. (2011), *Reconstructing the diets of Greek Byzantine populations (6<sup>th</sup>–15<sup>th</sup> centuries AD) using carbon and nitrogen stable isotope ratios*, American Journal of Physical Anthropology 146:569-581.
- Brickley M., Ives R. (2006), *Skeletal manifestations of infantile scurvy*, American Journal of Physical Anthropology 129:163-172.
- Brickley M., Ives R. (2008), *The bioarchaeology of metabolic bone disease*, Amsterdam & Boston: Elsevier/Academic Press.
- Brickley M., McKinley J.I. (2004), *Guidelines to the standards for recording human remains*, Institute of Field Archaeologists Paper 7, Southampton: BABAO & IFA.
- Brooks S.T., Suchey J.M. (1990), *Skeletal age determination based on the os pubis: A comparison of Ascadi-Nemeskeri and Suchey-Brooks methods*, Human Evolution 5:227-238.
- Buchet J.-L. (1986), *L'inhumation en basilique funéraire: observation, interprétations et commentaires* [in:] “Le matériel archéologique provenant des édifices religieux”, L. Buchet (ed.), Paris: Centre national de la recherche scientifique, pp. 69-73.
- Buchet J.-L., Sodini J.-P. (1984), *Les tombes* [in:] “Alikii II: La basilique double”, J.-P. Sodini, K. Kolokotsas (ed.), Athenes: Ecole Française d'Athenes, pp. 213-243.
- Buikstra J.E., Ubelaker D. (eds.) (1994), *Standards for data collection from human skeletal remains*, Fayetteville: Arkansas Archeological Survey.
- Cameron A. (1993), *The Mediterranean world in Late Antiquity, A.D. 395-600*, London: Routledge Press.
- Case D.T., Heilman J. (2005), *Pedal symphalangism in modern American and Japanese skeletons*, Homo 55:251-262.
- Dembo A., Imbelloni J. (1938), *Deformaciones intencionales del cuerpo humano de carácter étnico*, Buenos Aires: Jose Anesi.
- Dingwall E.J. (1931), *Artificial cranial deformation: A contribution to the study of the ethnic mutilations*, London: John Bale, Sons & Danielson.
- Doukata-Demertzi S. (2008), *Παλιόχωρα Μαρώνας: η ανασκαφή της παλαιοχριστιανικής βασιλικής και του μεσοβυζαντινού οικισμού*, Καβάλα: Υπουργείο Πολιτισμού, 12η Εφορεία Βυζαντινών Αρχαιοτήτων.
- Enchev Y., Nedelkon G., Atanassova-Timeva N., Jordanov J. (2010), *Paleoneurosur-*

- gical aspects of Proto-Bulgarian artificial skull deformations*, *Neurosurgical Focus* 29(6):E3.
- Fóthi E. (2000), *Anthropological conclusions of the study of Roman and Migration periods*, *Acta Biologica Szegediensis* 44:87-94.
- Goodman H.A., Rose J.C. (1990), *Assessment of systemic physiological perturbation from dental enamel hypoplasias and associated histological structures*, *Yearbook of Physical Anthropology* 33:59-110.
- Goodman H.A., Rose J.C. (1991), *Dental enamel hypoplasias as indicators of nutritional status* [in:] “Advances in dental anthropology”, M.A. Kelly, C.S. Larsen (eds.), New York: Wiley-Liss, pp. 279-294.
- Grimm V. (1995), *Fasting women in Judaism and Christianity in Late Antiquity* [in:] “Food in Antiquity”, J. Wilkins, F.D. Harvery, M.J. Dobson (eds.), Exeter UK: University of Exeter Press, pp. 225-240.
- Hillson S.W. (1979), *Diet and dental disease*, *World Archaeology* 11:147-162.
- Hillson S.W. (1986), *Teeth*, Cambridge: Cambridge University Press.
- Hrdlička A. (1922), *Aymara deformation in America*, *American Journal of Physical Anthropology* 5:400.
- Karadima Ch. (2015), *Το θέατρο και το Ιερό του Διονύσου στη Μαρόνεα*, Κομοτηνή: Εφορεία Αρχαιοτήτων Ροδόπης.
- Karadima Ch., Zambas C., Chatzidakis N., Thomas G., Doudoumi E. (2015), *The ancient theatre at Maroneia* [in:] “The architecture of the ancient Greek theatre. Acts of an international conference at the Danish Institute at Athens, 27-30 January 2012”, R. Frederiksen, E. Gebhard, A. Sokolicek (eds.), Aarhus: Aarhus University Press, pp. 253-266.
- Kardaras G. (2015), *The Antes. History and culture (4<sup>th</sup>–8<sup>th</sup> c.)*, Electronic Monographs 1, Athens: National Hellenic Research Foundation, Institute of Historical Research.
- Kazhdan A.P. (1991), *The Oxford dictionary of Byzantium*, New York: Oxford University Press.
- Kiszely I. (1978), *The origins of artificial cranial deformation in Eurasia from the sixth millennium B.C. to the seventh century A.D.*, BAR International Series 50, Oxford: BAR Publishing.
- Kustár A. (1999), *Facial reconstruction of an artificially restored skull of the 4<sup>th</sup> to the 5<sup>th</sup> century from the site of Mözs*, *International Journal of Osteoarchaeology* 5:325-332.
- Laiou A.E. (2002), *Political history: An outline* [in:] “The economic history of Byzantium”, A.E. Laiou (ed.), *Dumbarton Oaks Studies XXXIX*, Washington D.C.: The Dumbarton Oaks Research Library and Collection, pp. 9-28.
- Larsen C.S. (2015), *Bioarchaeology: Interpreting behavior from the human skeleton*, (2<sup>nd</sup> ed.), Cambridge: Cambridge University Press.

- Larsen C.S., Shavit R., Griffin M.C. (1991), *Dental caries evidence for dietary change: An archaeological context* [in:] "Advances in dental anthropology", M.A. Kelley, C.S. Larsen (eds.), New York: Wiley-Liss, pp. 179-202.
- Lefort J. (2006), *Population et démographie* [in:] "Le monde byzantin II. L'Empire byzantin (641-1204)" J.-C. Cheynet (ed.), Paris: Presses universitaires de France, pp. 203-219.
- Lieverse A.R. (1999), *Diet and the aetiology of dental calculus*, International Journal of Osteoarchaeology 9:219-232.
- Lillie M.C. (1996), *Mesolithic and Neolithic populations of Ukraine: Indications of diet from dental pathology*, Current Anthropology 37:135-142.
- Lorentz K.O. (2009), *The malleable body: Headshaping in Greece and the surrounding regions* [in:] "New directions in the skeletal biology of Greece", L. Schepartz, S. Fox, C. Bourbou (eds.), Hesperia Supplement 43, Princeton: American School of Classical Studies at Athens, pp. 75-98.
- Lovell N.C. (1997), *Trauma analysis in paleopathology*, Yearbook of Physical Anthropology 40:139-170.
- Lukacs J.R. (1989), *Dental paleopathology: Methods for reconstructing dietary patterns* [in:] "Reconstruction of life from the skeleton", M.Y. İşcan, K.A.R. Kennedy (eds.), New York: Alan R. Liss, pp. 261-286.
- Lukacs J.R. (2007), *Dental trauma and antemortem tooth loss in prehistoric Canary Islanders: Prevalence and contributing factors*, International Journal of Osteoarchaeology 17:157-173.
- Mango C. (1980), *Byzantium: The empire of New Rome*, London: Weidenfeld and Nicholson.
- Marcsik A., Pap I. (2000), *Paleopathological research in Hungary*, Acta Biologica Szegediensis 44:103-108.
- Maresh M.M. (1970), *Measurements from roentgenograms: Heart size, long bone lengths, bone, muscles and fat widths, skeletal maturation*, [in:] "Human growth and development", R.W. McCammon (ed.), Springfield: Charles C. Thomas, pp. 155-200.
- Martin R., Saller K. (1957), *Lehrbuch der Anthropologie*, Stuttgart: G. Fischer.
- Mays S., Brickley M., Ives R. (2006), *Skeletal manifestations of rickets in infants and young children in a Prehistoric population from England*, American Journal of Physical Anthropology 129:362-374.
- Meindl R.S., Lovejoy O.C. (1989), *Age changes in the pelvis: implications for palaeodemography* [in:] "Age markers in the human skeleton", M.Y. İşcan (ed.), Springfield: Charles C. Thomas, pp. 137-168.
- Mensforth R.P., Lovejoy C.O., Lallo J.W., Armelagos G.J. (1978), *The role of constitutional factors, diet, and infectious disease in the etiology of porotic hyperostosis and periosteal reactions in prehistoric infants and children*, Medical Anthropology

2:1-59.

- Merbs C.F. (1983), *Patterns of activity-induced pathology in a Canadian Inuit population*, National Museum of Man Mercury Series, Archaeological Survey of Canada 119, Ottawa: National Museum of Man.
- Mitchell S. (2007), *A history of the Late Roman Empire, AD 284-641: The transformation of the ancient world*, Malden & Oxford: Blackwell.
- Molnár M., János I., Szücs L., Szathmáry L. (2014), *Artificially deformed crania from the Hun-Germanic period (5<sup>th</sup>-6<sup>th</sup> century AD) in northeastern Hungary: Historical and morphological analysis*, *Neurosurgical Focus* 36(4):e1.
- Morrisson C., Sodini J.-P. (2002), *The sixth-century economy* [in:] “The economic history of Byzantium”, A.E. Laiou (ed.), *Dumbarton Oaks Studies XXXIX*, Washington D.C.: The Dumbarton Oaks Research Library and Collection, pp. 171-220.
- Musgrave J.H. (1976), *Appendix A: The human remains*, *Annual of the British School at Athens* 71:40-46.
- Ortner D.J. (2003), *Identification of pathological conditions in human skeletal remains*, London: Academic Press.
- Ortner J.D., Mays S. (1998), *Dry-bone manifestations of rickets in infancy and early childhood*, *International Journal of Osteoarchaeology* 8:45-55.
- Ortner D., Kimmerle E.H., Diez M. (1999), *Probable evidence of scurvy in subadults from archaeological sites in Peru*, *American Journal of Physical Anthropology* 108: 321-331.
- Ortner D.J., Butler W., Cafarella J., Milligan L. (2001), *Evidence of probable scurvy in subadults from archaeological sites in North America*, *American Journal of Physical Anthropology* 114:343-351.
- Ostrogorsky G. (1969), *History of the Byzantine state*, New Brunswick: Rutgers University Press.
- Plomp K.A., Roberts C.A., Vidarsdottir U.S. (2012), *Vertebral morphology influences the development of Schmorl's nodes in the lower thoracic vertebrae*, *American Journal of Physical Anthropology* 149:572-582.
- Plomp K.A., Roberts C.A., Vidarsdottir U.S. (2015), *Does the correlation between Schmorl's nodes and vertebral morphology extend into the lumbar spine?*, *American Journal of Physical Anthropology* 157:526-534.
- Popkonstantinov K. (2008), *Bulgars (Proto-Bulgarians)*, *Encyclopaedia of the Hellenic World. Black Sea*, visited 13/4/2016.
- Resnick D., Niwayamma G., Goergen T.G. (1975), *Degenerative disease of the sacroiliac joint*, *Investigative Radiology* 10:608-621.
- Rohn A.H., Barnes E., Sanders G.D.R. (2009), *An Early Ottoman cemetery at ancient Corinth*, *Hesperia* 78(4):501-615.



- Rothschild B. (2015), *Spondyloarthropathy, spondyloarthritis, axial spondyloarthritis: A rose by any other name?*, Journal of Rheumatic Diseases and Treatment 1:e010.
- Saponetti S.S., Emanuel P., Scattarella V. (2005), *Paleobiologia di un campione scheletrico tardoantico proveniente dal complesso paleocristiano di San Giusto (Lucera V-VII secolo d.C.)* [in:] “Paesaggi e insediamenti rurali in Italia meridionale fra Tardoantico e Altomedioevo”, G. Volpe, M. Turchiano (eds.), Bari: Edipuglia, pp. 315-328.
- Scheuer L., Black S. (2000), *Developmental juvenile osteology*, San Diego: Academic Press.
- Schendl A.S., Walker G., Kamisugi A. (1980), *Hawaiian craniofacial morphometrics: Average Mokapuian skull, artificial cranial deformation, and the ‘rocker’ mandible*, American Journal of Physical Anthropology 52:491-500.
- Sołtysiak A. (2006), *The plague pandemic and Slavic expansion in the 6<sup>th</sup>-8<sup>th</sup> centuries*, Archaeologia Polona 44:339-364.
- Stathakopoulos Ch.D. (2004), *Famine and pestilence in the Late Roman and Early Byzantine Empire: A systematic survey of subsistence crises and epidemics*, Aldershot: Ashgate.
- Stuart-Macadam P. (1985), *Porotic hyperostosis: Representative of a childhood condition*, American Journal of Physical Anthropology 66:391-398.
- Todd T.W. (1920), *Age changes in the pubic bone: I. The white male pubis*, American Journal of Physical Anthropology 3:285-334.
- Todd T.W. (1921), *Age changes in the pubic bone: II, III, IV*, American Journal of Physical Anthropology 4:1-70.
- Torres-Rouff C., Yablonsky L.T. (2005), *Cranial vault modification as a cultural artifact: A comparison of the Eurasian steppes and the Andes*, Homo – Journal of Comparative Human Biology 56:1-16.
- Touger-Decker R., van Loveren C. (2003), *Sugars and dental caries*, American Journal of Clinical Nutrition 78:881-892.
- Tritsaroli P. (2008), *Το νεκροταφείο εκτός των τειχών της βυζαντινής Μαρώνειας. Βιοαρχαιολογική ανάλυση και ταφικά έθιμα*, Archaeological Work in Macedonia and Thrace 20:31-43.
- Tritsaroli P. (2011), *Artificial cranial modification on a female skeleton from the Byzantine site of Maroneia (Thrace, Greece)*, International Journal of Osteoarchaeology 21:464-478.
- Tritsaroli P. (2017), *Life and death at Early Byzantine Akraiphnio, Greece: A biocultural approach*, Anthropologie (Brno) 55:243-263.
- Trotter M. (1970), *Estimation of stature from intact long limb bones* [in:] “Personal identification in mass disasters”, T.D. Steward (ed.), Washington DC: Smithsonian Institution, pp. 71-83.

- Ubelaker D.H. (1989), *Human skeletal remains: Excavation, analysis, interpretation*, 2<sup>nd</sup> ed., Washington: Smithsonian Institution Press.
- Waldron T. (2009), *Palaeopathology*, Cambridge: Cambridge University Press.
- Waldron T., Rogers J. (1990), *An epidemiologic study of sacroiliac fusion in some human skeletal remains*, *American Journal of Physical Anthropology* 83:123-127.
- Walker P.L., Bathurst R.R., Richman R., Gjerdrum T., Andrushko V.A. (2009), *The causes of porotic hyperostosis and cribra orbitalia: A reappraisal of the iron-deficiency-anemia hypothesis*, *American Journal of Physical Anthropology* 139:109-125.
- Wesolowsky A.B. (1973), *The skeletons of Lerna hollow*, *Hesperia* 42:340-351.
- Weston D.A. (2012), *Nonspecific infection in paleopathology: Interpreting periosteal reactions* [in:] "A companion to paleopathology", A.L. Grauer (ed.), Chichester: Blackwell Publishing, pp. 492-512.
- Wood J.W., Milner G.R., Harpending H.C., Weiss K.M. (1992), *The osteological paradox: Problems of inferring prehistoric health from skeletal samples*, *Current Anthropology* 33:343-370.