

Human remains from Robot Aghaj, Iran, 2017

Arkadiusz Sołtysiak^{*1}, Majjid Montazerzohouri²,
Javad Hosseinzadeh²

¹ Department of Bioarchaeology,
Institute of Archaeology, University of Warsaw,
Krakowskie Przedmieście 26/28, 00-927 Warsaw, Poland
email: a.soltysiak@uw.edu.pl (corresponding author)

² Department of Archaeology, University of Kashan,
Qotbe Ravandi Blv., Kashan, Iran

One of many historical underground structures in the Markazi province, Iran, is located near the modern village Robot Aghaj, c. 20km north to the town Khomein (33°49'26"N, 50°05'55"E). Partially filled with soil, it was excavated in February and March 2017 by a team from the University of Kashan directed by Majjid Montazerzohouri. The structure contains one long tunnel with a few shorter ones and eleven rooms (**Figure 1**). Most artifacts retrieved from the site were dated to the Khwarazmian Period (late 12th – early 13th century CE).

Although sites such as Robot Aghaj were not used as a burial place, a few human remains were found. Together with an animal bone, a human skull was placed on a folded mat in the middle of Room 1 (**Figure 2**). The skull most likely belong to a mature female based on cranial morphology and the degree of dental wear, although most sutures were still open or minimally obliterated. The right side of the cranium and mandible were almost complete, but the left side was broken into small and medium fragments. On the left side, especially in the inner table of the cranial vault, irregular black staining and a higher degree of weathering were observed suggesting that the left side was exposed longer than the right (cf. Sołtysiak & Feter 2017). A small area of porosity without hyperostosis developed on the right frontal bone near pterion (**Figure 3**). Similarly, the bones of the palate were porous suggesting metabolic disease, perhaps osteoporosis, rickets, or scurvy (cf. Pitre et al. 2016). The alveolar process was clearly reduced by c. 3–4mm due to periodontal disease, a condition that progresses with age (Alt et al. 1998). Also, some medium-sized areas of dental calculus were present, especially on the molars. The teeth were worn rather flat, with dentin cupping that may be the result of an abrasive diet (Coupal & Sołtysiak 2017). Linear enamel hypoplasia was present on the upper second incisors and third molars as well as on the right lower second molar whose asymmetrical pattern suggests that the hypoplastic lines do not reflect systemic stress and may be the effect of premature birth (Aine et al. 2000). Dental caries affected 6 per 19 preserved teeth

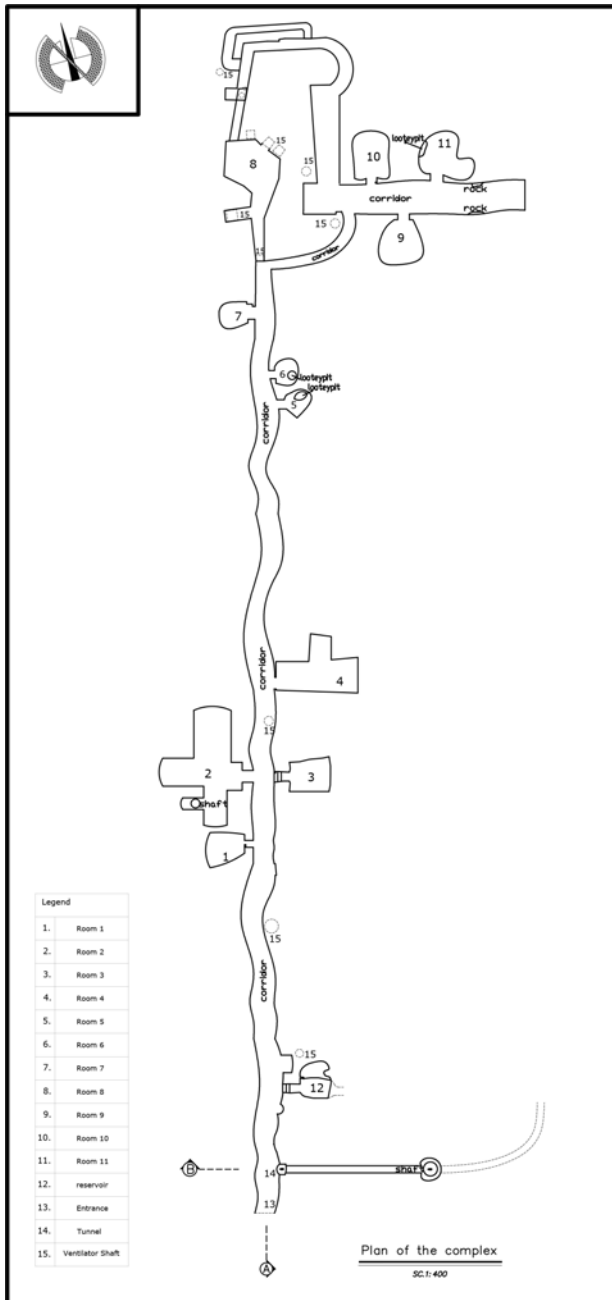


Figure 1. Robot Aghaj, plan of the underground structure.



Figure 2. Original position of the skull on the floor of Room 1.



Figure 3. Cranial porosity on the skull from Room 1.



Figure 4. Damaged central deciduous incisor of the child from Room 3. Scale bar 1 mm.

(including 5 per 11 molars) and lesions were located both on cemento-enamel junction and on the occlusal surfaces of molars, which suggests a diet rich in fermentable sugars (cf. Sołtysiak 2012).

Additionally, a fragment of a left maxilla together with a fragment of a damaged mandible of a 3-years old individual were discovered at the entrance to Room 3. This time only slight porosity was observed on the palate, small enamel defects on the upper deciduous canines and no dental caries. All preserved upper incisors (left central and both lateral ones) were damaged on their labial side, c. 2mm from the cemento-enamel junction (**Figure 4**). This broad horizontal line was most likely the effect of some unknown lifetime cultural practice. No parallel damage was observed on the canines.

Acknowledgements. We thank students of University of Kashan for taking a part in excavations and also the Cultural Heritage Organization Center of Markazi province, specially Esmail Sharahi, for their support.

References

- Aine L., Backstrom M.C., Maki R., Kuusela A.-L., Koivisto A.-M., Ikonen R.-S., Maki M. (2000), *Enamel defects in primary and permanent teeth of children born prematurely*, *Journal of Oral Pathology and Medicine* 29(8):403–409.
- Alt K.W., Rösing F.W., Teschler-Nicola M. (1998), *Dental anthropology: Fundamentals, limits, and prospects*, Wien & New York: Springer.
- Coupal I., Sołtysiak A. (2017), *Dental erosion in archaeological human remains: A critical review of literature and proposal of a differential diagnosis protocol*, *Archives of Oral Biology* 84:50–57.
- Pitre M.C., Stark R.J., Gatto M.C. (2016), *First probable case of scurvy in ancient Egypt at Nag el-Qarmila, Aswan*, *International Journal of Paleopathology* 13:11–19.
- Sołtysiak A. (2012), *Comment: Low dental caries rate in Neandertals: The result of diet*

or the oral flora composition?, HOMO – Journal of Comparative Human Biology 63(2):110–113.

Sołtysiak A., Fetner R.A. (2017), *Taphonomy of human remains exposed in burial chambers, with special reference to Near Eastern hypogea, ossuaries and burial caves* [in:] “Engaging with the dead: Exploring changing human beliefs about death, mortality and the human body,” J. Bradbury, C. Scarre (eds.), Oxford & Havertown: Oxbow Books, pp. 67–76.