

## Human remains from Mansourkotti, Korti and Ousli East, Sudan, 2014–2018

Iwona Kozieradzka-Ogunmakin

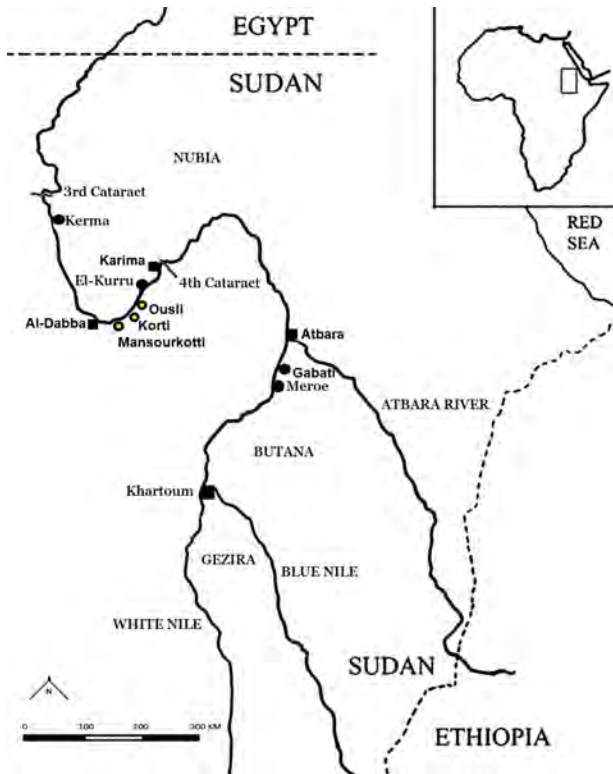Department of Earth and Environmental Sciences,  
Faculty of Science and Engineering, University of Manchester,  
3.503 Stopford Building, Oxford Road, M13 9PT, Manchester, United Kingdom  
email: iwona.kozieradzka-ogunmakin@manchester.ac.uk

---

The Dabba-Dam Archaeological Survey Project (DDASP), an initiative sponsored by the Qatar-Sudan Archaeological Project and the National Corporation for Antiquities and Museums (NCAM) in Sudan, set out to survey the area on the left bank of the Nile between the town of Al-Dabba and the Merowe Dam site at the Fourth Cataract (**Figure 1**). Between 2013 and 2018, an area of 760km<sup>2</sup> was surveyed and a total of 234 new archaeological sites were recorded, including three Late Meroitic (AD 90–350) cemeteries (Hassan Bakheit 2015, 2016; Abdelsawi 2019). The cemeteries at Mansourkotti (DDASP DS2), Korti (DDASP DS128) and Ousli East (DDASP DS231) (**Figure 1**) are located in close proximity to modern settlements exposing them to progressive destruction due to human actions and natural factors.

Mansourkotti is a modern village located approximately 40km upstream from Al-Dabba and some 305km north of Khartoum. The Late Meroitic cemetery (DDASP DS2; 18°02′0.1″N, 31°20′01″E) lies to the north of the village and approximately 250m south of the Nile, covering an area of 460×200m (Hassan Bakheit 2015, 2016). A total of 88 tumuli—rounded gravel mounds—have been recorded along a likely old Nile terrace, with 25 of the structures having been excavated in the course of two field seasons.

The modern village of Korti is located approximately 30km upstream from Mansourkotti. The cemetery (DDASP DS128; 18°05′4.4″N, 31°35′48″E) with over 20 graves identified during the survey has been partially excavated by the NCAM archaeological team. The village of Ousli is located approximately 15km upstream from Korti and 40km west from the modern town of Karima. The Late Meroitic to Post-Meroitic cemetery (DDASP DS231; 18°12′10.8″N, 31°41′5.7″E) has been identified east of the village and is currently endangered by a growing modern settlement. Archaeological excavations conducted by NCAM in February 2018 aimed to document the location of the identified graves and to recover several inhumations (**Figure 2**).



**Figure 1.** Map of Sudan with locations of the sites of interest.  
 Drawn by I. Kozieradzka-Ogunmakin.

Partial excavation of the three cemeteries was focused primarily on the most endangered burials. The circular mound graves were furnished with ceramic vessels and items of personal adornment (Hassan Bakheit 2015, 2016; Abdelsawi 2019). Often disturbed and disarticulated skeletal remains provided primary evidence of looting that most likely took place in antiquity (e.g., **Figure 2**). Excavation and recording of burials was conducted by the NCAM team. Recovered artefacts and skeletal remains were transferred to Khartoum and are stored at NCAM. Permission to study the human remains as part of the ‘Environmental Changes and the Collapse of the Meroitic Kingdom, Sudan’ project was granted in 2018 and access was given to a total of 17 inhumations.

The main focus of the study was the recording of markers of developmental and adult stress, including enamel hypoplasia, ectocranial porosity (orbital and vault lesions), trauma, and generalised infection in order to shed light on the physical health status of the people during the Late Meroitic Period—a time of climate change and



Figure 2. Looted burial, Ousli East T.9/54. Photograph by NCAM-DDASP.

increased aridity in the region (Machado et al. 1998; Williams 2009:10–11). Cultural chronology of the cemeteries was verified with radiocarbon dating (Table 1). Osteological findings recorded in the present Late Meroitic assemblage were compared with the results of a comprehensive study of a Meroitic (c. 300 BC–AD 350) and Post-Meroitic (c. 350–600 AD) population from Gabati (Judd 2012), a site located some 50km upstream from the town of Atbara (Figure 1).

Table 1. AMS  $^{14}\text{C}$  radiocarbon dates of human remains from the Late Meroitic cemeteries of interest.

Site/Tomb ID	Material	Lab. No. <sup>1</sup>	Uncalibrated age (BP)	Calibrated age (BC/AD) <sup>2</sup>
Korti T.14	bone	Poz-101747	1855±30	89–245 AD
Korti T.23	bone	Poz-101751	1890±30	76–231 AD
Mansourkotti T.25	bone	Poz-101749	1935±30	17–205 AD
Mansourkotti T.35	bone	Poz-101744	1835±30	125–318 AD
Ousli East T.6	tooth	GdA-5762	1720±40	246–415 AD
Ousli East T.42	bone	GdA-5758	1740±30	245–402 AD

<sup>1</sup> AMS dating was conducted by Poznań Radiocarbon Laboratory (Poz) and Gliwice Radiocarbon Laboratory (GdA).

<sup>2</sup> The radiocarbon ages were modelled in OxCal v.4.4.3 using the IntCal20 calibration curve (Bronk Ramsey 2009; Reimer et al. 2020). The calibrated ages of the samples are given at 95.4% probability.

The examination and recording of the skeletal remains was conducted using the standard protocols presented by Buikstra and Ubelaker (1994). Dental age estimation in sub-adults was based on AlQahtani and colleagues (2010). Despite disarticulation and fragmentation of the skeletons caused by looting activities, the majority of the individuals were nearly complete, with the exception of the remains recovered from Korti T.5 and T.16B (Table 2). Males represented 53% (n=9 of 17) of the individuals in comparison to 41% females (n=7 of 17). Biological sex of one individual (Korti T.16C)—an infant aged approximately 5 to 7 months at the time of death—remained undetermined (Table 2). A total of two individuals (12%) in the assemblage were subadults (<20 years) (Table 3). Adult individuals (20+ years) constituted 88% (n=15) of the assemblage with young adults (20–35 years) representing the majority in the adult sub-group (53%; n=8) (Table 3).

Dental completeness was overall good with the exception of three adult individuals with poorly preserved dentition (Korti T.22) or no dentition present (Mansourkotti T.35 and Korti T.5) due to skeletal incompleteness (Table 4). In total, 4 of 13 individuals (31%) experienced multiple ante-mortem tooth loss (AMTL), including a middle-adult female from Mansourkotti T.78 who presented a largely edentulous maxillary arch (Figure 3). In all four cases, AMTL affected distal teeth

**Table 2.** Biological data and completeness of the skeletons recovered from the Late Meroitic burials.

Site	Tomb ID	Sex	Age-at-death (years)	Completeness (%)
Mansourkotti	T.25	M	20–25	75–100
	T.31	M	40–50	75–100
	T.35	M	35–45	75–100
	T.78	F	40–50	75–100
Korti	T.5	M?	20+	<25
	T.14	M	35–45	75–100
	T.16A	M	25–30	75–100
	T.16B	M	35–45	50–75
	T.16C	?	<1	75–100
	T.22	F	25–30	75–100
	T.23	M	25–30	75–100
	T.26	F	16–18	75–100
Ousli East	T.6	F	20–25	75–100
	T.9	F	20–25	75–100
	T.13	F	45–60	75–100
	T.17	M	25–35	75–100
	T.42	F	25–35	75–100

and molars in particular. The latter are susceptible to carious lesions due to their complex occlusal surfaces, whereas smooth crown sides are less frequently affected. AMTL could be attributed to carious or non-carious pulp exposure and resulting inflammation with subsequent abscess formation. The latter was recorded in 4 of 14 individuals (29%), including three individuals with multiple periapical abscesses.

Caries were recorded in only one individual—a male from Korti T.16B—of 13 (8%) skeletons with preserved dentition, affecting a total of five individual teeth. Overall, the lesions affected 1.5% of the dental assemblage (5 per 326 teeth). The le-

**Table 3.** Sex and age-at-death distribution in the Late Meroitic skeletal assemblage.

Sex	Infants 0–3	Children >3–12	Adolescents >12–20	Young Ad. >20–35	Middle Ad. >35–50	Old Ad. 50+
M	–	–	–	4	4	–
F	–	–	1	4	1	1
?	1	–	–	–	–	–
Total	1	–	1	8	5	1

**Table 4.** Dental health in the Late Meroitic skeletal assemblage.

Site	Tomb ID	Teeth No.	AMTL <sup>2</sup>	Caries	Abscess	LEH <sup>3</sup>	DC <sup>3</sup>
Mansour- kotti	T.25	32	0	0	0	–	1
	T.31	22	0	0	0	–	1
	T.35	0	–	–	–	–	–
	T.78	16	1*	0	1	0	1
Korti	T.5	0	–	–	–	–	–
	T.14	16	1*	–	1*	0	1
	T.16A	17	0	0	0	–	1
	T.16B	25	1*	1*	0	0	1
	T.16C	0	–	–	–	–	–
	T.22	4	–	–	0	–	0
	T.23	32	0	0	0	–	1
	T.26	32	0	0	0	1*	1
Ousli East	T.6	31	0	0	0	0	1
	T.9	26	0	0	0	1	1
	T.13	24	1*	0	1*	–	1
	T.17	20	0	0	1*	–	1
	T.42	29	0	0	0	0	1
Total		326	4/13	1/13	4/14	2/7	13/14

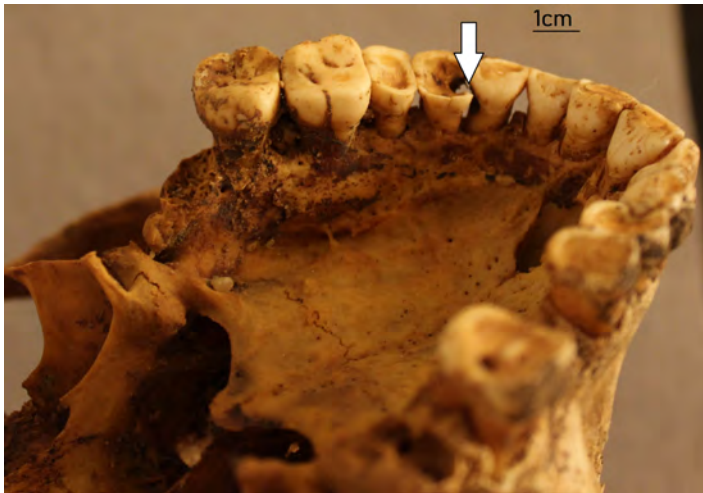
<sup>1</sup> Key: 0 – not present; 1 – present; – – not observable; \* – multiple

<sup>2</sup> AMTL – ante-mortem tooth loss      <sup>3</sup> LEH – linear enamel hypoplasia

<sup>4</sup> DC – dental calculus



**Figure 3.** Largely edentulous maxillary arch; middle-adult female from Mansourkotti T.78. Photograph by I. Kozieradzka-Ogunmakin.



**Figure 4.** Interproximal caries in the maxillary canine and first premolar; middle-adult male from Korti T.16B. Photograph by I. Kozieradzka-Ogunmakin.

sions were recorded on the interproximal surfaces, extending to the cemento-enamel junction of the right maxillary canine and first premolar (**Figure 4**), the left maxillary second molar, the left mandibular first premolar, and led to complete destruction of the second premolar leaving only the root present. A similar frequency of dental

caries was recorded in a contemporaneous Meroitic population from Gabati, where 8 of 91 (8.8%) individuals or 8 of 619 (1.3%) permanent teeth were affected (Judd 2012: Table 7.1). In comparison, the frequency of dental caries recorded in a Post-Meroitic/Medieval assemblage was negligible, with only one of 32 individuals (3.1%) and one in 819 permanent teeth (0.1%) affected. Caries are a multifactorial disease (Ferraro & Vieira 2010) and their low frequency in these assemblages could be due to environmental and dietary factors among others (Buckley et al. 2014).

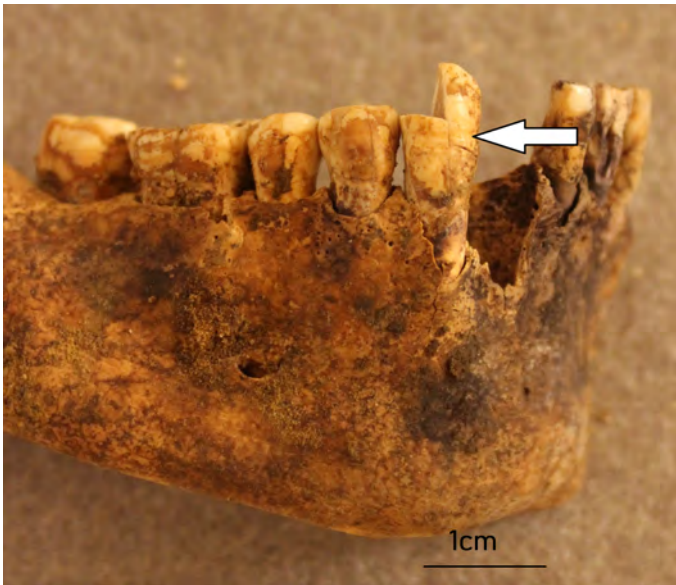Evidence of linear enamel hypoplasia (LEH) that results from episodic growth disruption experienced during childhood was observed in 2 of 7 individuals (29%) with the anterior teeth present; no LEH was recorded in the posterior teeth. Single horizontal lines were recorded on the mandibular canines of an adolescent female from Korti T.26 (Figure 5), whereas two lines were observed on the right maxillary central incisor—the left counterpart was lost post-mortem—of a young-adult female from Ousli East T.9. The formation of LEH is associated with episodes of physiological stress during childhood, such as infectious disease, nutritional deficiency, or weaning (Goodman & Rose 1990; Hillson 2019). The positioning of the enamel defects in

Table 5. Skeletal health in the Late Meroitic skeletal assemblage.

Site	Tomb ID	CO <sup>2</sup>	PH <sup>3</sup>	NSI <sup>4</sup>	Trauma	SJD <sup>5</sup>	NSJD <sup>6</sup>
Mansour-kotti	T.25	0	0	0	0	1	0
	T.31	0	0	0	0	1	1
	T.35	–	–	0	1	1	1
	T.78	0	0	0	0	1	1
Korti	T.5	–	–	0	1	–	–
	T.14	0	1	0	0	1	1
	T.16A	0	0	0	1	1	0
	T.16B	0	0	1	1*	1	1
	T.16C	1	0	1	1	0	0
	T.22	0	0	0	1*	0	0
	T.23	0	1	0	1*	0	0
	T.26	0	0	0	1	0	0
Ousli East	T.6	1	1	1	1*	1	0
	T.9	0	0	0	1	0	0
	T.13	0	1	0	1*	1	1
	T.17	0	0	1	1*	1	1
	T.42	0	1	0	0	0	0
Total		3/15	6/15	2/15	12/17	10/16	7/16

<sup>1</sup> Key: 0 – not present; 1 – present; – – not observable; \* – multiple

<sup>2</sup> CO – cribra orbitalia    <sup>3</sup> PH – porotic hyperostosis    <sup>4</sup> NSI – non-specific infections    <sup>5</sup> SJD – spinal joint disease    <sup>6</sup> NSJD – non-spinal joint disease




**Figure 5.** A single LEH on the right mandibular canine; adolescent female from Korti T.26. Photograph by I. Kozieradzka-Ogunmakin.



**Figure 6.** Orbital porosity with coalescing foramina (right orbit) in an infant from Korti T.16C. Photograph by I. Kozieradzka-Ogunmakin.





**Figure 7.** Porosity and new bone formation on the body of the sphenoid in an infant from Korti T.16C. Photograph by I. Kozieradzka-Ogunmakin.

the mid-crown of the canines in the female from Korti T.26 and near the cemento-enamel junction in the female from Ousli East T.9 suggests the stress episodes took place when the individuals were approximately 3 years and 3 to 4 years old respectively (Hillson 2019: Figure 9.3), though, neither showed evidence of skeletal stress markers (Table 5). In a contemporaneous Meroitic population from Gabati, only one adult female (1 of 112; 0.9%) showed evidence of dental enamel hypoplasia (Judd 2012: Table 5.9).

Calculus was recorded predominantly on the posterior teeth as slight or—less commonly—moderate deposits. All but one adult individual ( $n=14/15$ , 93%) exhibited evidence of calculus.

Several cases of skeletal non-specific stress indicators, manifested as porosity on the ectocranial surface of the skull (orbital and vault lesions) and periosteal new bone formation on the ectocranial surface of the skull and on the long bones, were recorded in the Late Meroitic DDASP assemblage (Table 5). In total, 6 of 15 individuals (40%) demonstrated cranial porosities. Bilateral orbital lesions (*cribra orbitalia*) were recorded in two individuals (13%), of which one—a young female from Ousli East,



**Figure 8.** Extensive periosteal new bone formation on the right fibular and tibial diaphyses; young-adult male from Ousli T.17. Photograph by I. Koziaradzka-Ogunmakin.

T.6—also manifested porotic lesions on the ectocranial surface of the vault. Orbital lesions observed in an infant from Korti T.16C (**Figure 6**) and a young female from Ousli East T.6 ranged from porosity only to porosity with coalescence of foramina, and were a mixture of active and healed lesions at the time of death. Vault lesions ranged from barely discernible to true porosity. *Cribra orbitalia* and porotic hyperostosis are considered evidence of iron-deficiency anaemia, with haemolytic and megaloblastic anaemias also suggested as causative factors of these lesions (Nikita 2017:308). In addition to *cribra orbitalia*, the infant from Korti T.16C showed extensive evidence of new bone formation on the ectocranial surface of the skull, abnormal porosity and new bone formation on the sphenoid (**Figure 7**) and the basilar portion of the occipital bone, the maxillae and the mandible, and postcranial skeletal elements, including the scapulae and long bones. These pathological lesions and their distribution could be associated with infantile scurvy, a nutritional deficiency of vitamin C (Moore & Koon 2017; Ortner & Erickson 1997; Ortner et al. 2001). Certain factors, including gastro-intestinal disease, malaria and trauma—the latter sustained by the infant at the time of birth—could increase an individual's requirement for vitamin C (Halcrow et al. 2014). In the Meroitic assemblage from Gabati, 18 of 90 (20%) adults and 7 of 15 (46.7%) sub-adults showed evidence of *cribra orbitalia* (Judd 2012: Table 7.3), in comparison to one of 13 (7.7%) adults and one of 2 (50%) sub-adults in the Late Meroitic DDASP assemblage (**Table 5**).

A total of three adult individuals (M=2; F=1; 20%) exhibited periosteal new bone formation on their tibial and fibular diaphyses (**Figure 8**; **Table 5**), which could

be generated due to a number of different mechanisms, including excessive physical activity, trauma, joint disease, nutritional imbalance, and/or infection (Chen et al. 2012; Weston 2011). A higher prevalence of osteoperiostitis of the tibia was recorded in the Meroitic assemblage from Gabati, where 22 of 80 (27.5%) adults exhibited deposition of new bone (Judd 2012: Table 6.23).

Skeletal and soft tissue trauma (*myositis ossificans*) was the most frequently recorded pathology in the Late Meroitic DDASP assemblage, affecting 12 of 17 individuals (71%) in all age groups represented (Table 5). Overall, 6 males and 5 females showed evidence of trauma, with a total of 6 individuals—representing 35% of the assemblage—displaying evidence of multiple locations of skeletal trauma. Evidence of injuries was recorded in various parts of the skeleton, including the cranium (n=1), clavicle (n=2), humerus (n=1), distal radius (n=2), distal ulna (n=1), ribs (n=2), vertebrae (n=3), and the pelvis (n=1), as well as metacarpals, metatarsals and phalanges (n=5).

A single case of cranial trauma was recorded in a young-adult male from Korti T.23. A well-healed puncture fracture—visible as a circular depression (c. 9mm in diameter)—was sustained to the left frontal bone; the injury was likely caused by a blunt implement or a projectile weapon (Guyomarc’h et al. 2010), for example a sling or throw-stick. The individual also demonstrated medial angulation of the left humeral shaft—a suspected greenstick fracture, as well as healed fractures to the left lower ribs, and a healed oblique fracture to the left fifth metacarpal. The recorded fractures could have been accidental or resulted from interpersonal violence, such as the frontal puncture fracture. A low incidence of skeletal evidence of interpersonal violence was also recorded in the Meroitic and Post-Meroitic assemblages from Gabati (Judd 2012:70–71), contrary to the view that the Late Meroitic and Post-Meroitic periods were times of social unrest and conflict with neighbouring groups, both associated with the collapse of the Meroitic kingdom and formation of smaller independent polities (Edwards 2004:183).

Fractures to the clavicle were recorded in an older female from Ousli East T.13 and an infant from Korti T16C. The former individual also sustained a Colles fracture, a transverse metaphyseal fracture to the left distal radius resulting in dorsal displacement and angulation (Colles 2006), both likely to have resulted from accidental falls. A unilateral mid-shaft fracture to the left clavicle recorded in the infant from Korti T16C was likely birth-related (Figure 9). Clavicle fracture is the most frequent birth injury in newborns, accounting for nearly 90% of modern birth-related fractures (Moczygemba et al. 2010; Monjok 2008; Pecci & Kreher 2008). This type of injury is sustained during a difficult delivery and is often the result of shoulder dystocia caused by excessive latero-medial pressure on the newborn’s shoulders during passage through the birth canal. To date, there are very few archaeological cases of such a fracture reported in the literature (e.g. Dupras et al. 2015).



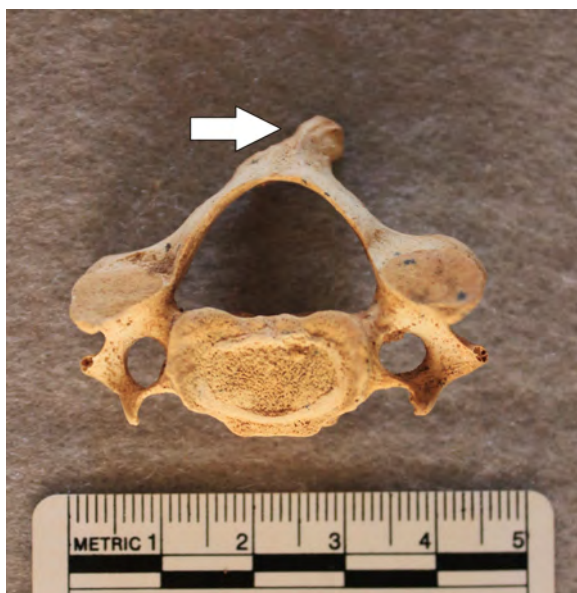**Figure 9.** An actively healing mid-shaft fracture to the left clavicle (superior view) in an infant from Korti T.16C. Photograph by I. Kozieradzka-Ogunmakin.



**Figure 10.** A misaligned healed fracture to the right inferior pubic ramus (medial view); young-adult male from Ousli East T.17. Photograph by I. Kozieradzka-Ogunmakin.



**Figure 11.** *Os acromiale* in the left scapula (lateral view); young-adult male from Ousli East T.17. Photograph by I. Kozieradzka-Ogunmakin.



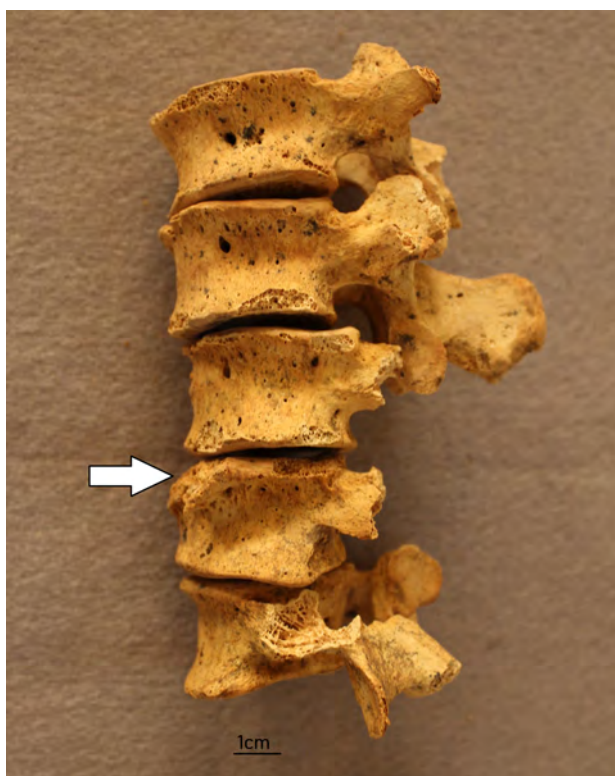
**Figure 12.** An avulsion fracture to the spinous process of C4 (superior view); young-adult female from Ousli East T.6. Photograph by I. Kozieradzka-Ogunmakin.



**Figure 13.** Spondylolysis in L5 (inferior view); young-adult female from Korti T.22.  
Photograph by I. Kozieradzka-Ogunmakin.

A young-adult male from Ousli East T.17 sustained a fracture to the left superior and the right inferior pubic rami (**Figure 10**). The fractured bones were slightly misaligned and healed with visible deformity; the stability of the pelvic ring, however, was not compromised. Pubic rami fractures can result from a direct blow or lower-energy impact, such as a fall, and are the most common pelvic fractures in older individuals according to modern clinical data (Hill et al. 2001). Also recorded in this individual was a unilateral case of *os acromiale*, an anatomical variant that represents an unfused secondary ossification centre of the acromion of the scapula. The affected bone—the left scapula—demonstrated a failed union of the secondary ossification centre at the junction of the meso- and meta-acromion (**Figure 11**), the most common location of the variant. *Os acromiale* has a modern incidence of 8% and is more common in males (Edelson et al. 1993; Sammarco 2000). A similar variant was recorded in the left scapula of a young-adult female from Korti T.22. Acromion fracture was considered as a differential diagnosis in both cases.

Vertebral stress fractures were recorded in three adults (3 of 14; 21.4%). A young-adult female from Ousli East T.6 sustained an avulsion fracture to the spinous process



**Figure 14.** L4 showing the loss of a wedge-shaped portion of the body margin due to traumatic disc herniation or brucellar spondylitis; young-adult male from Mansourkotti T.25. Photograph by I. Kozieradzka-Ogunmakin.

of the fourth cervical vertebra (**Figure 12**), resulting in sharp deviation from the sagittal axis as a result of a forceful muscle pull. A further two individuals—a middle-adult male from Korti T.16B and a young-adult female from Korti T.22—showed a case of spondylolysis, a stress fracture in the *pars interarticularis* of the vertebral arch associated with heavy manual labour and lifting (Merbs 1989). In both cases, the injury was bilateral and affected the fifth lumbar vertebra (**Figure 13**). In the Meroitic Gabati assemblage, the injury was sustained by 6 of 82 (7.3%) adult individuals and by 2 of 32 (6.3%) adults from the Post-Meroitic sub-group (Judd 2012:72).

Evidence of intervertebral disc herniations in the vertebral body endplates in the form of Schmorl's nodes (Waldron 2009:45) were recorded in the lower thoracic vertebrae of a young-adult male from Ousli East T.17 (1 of 15; 6.7%). In comparison, 29 individuals (24.5%) from Gabati showed at least one lesion (Judd 2012:72). A case of traumatic anterior disc herniation with differential diagnosis of brucellar spondyli-



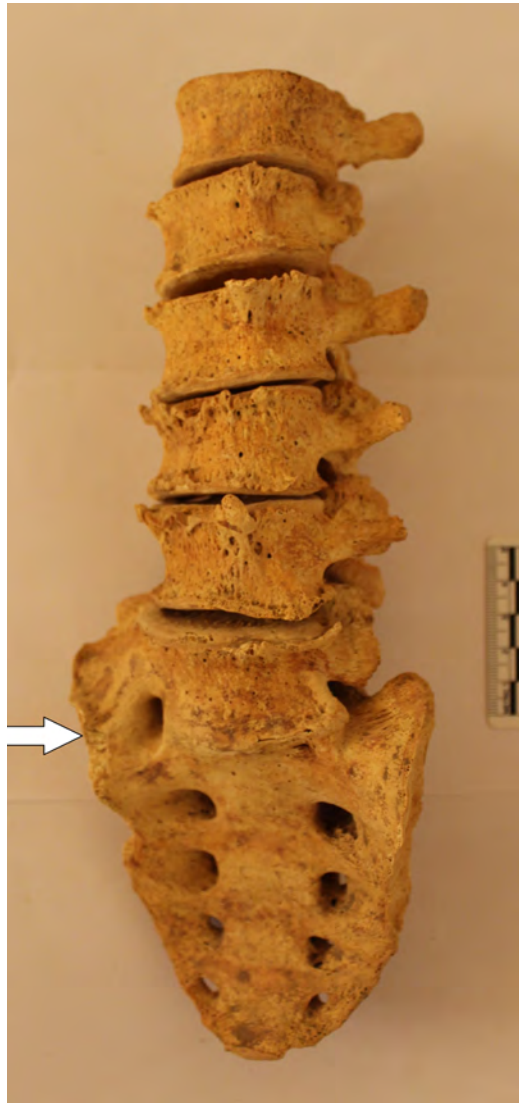
**Figure 15.** Marginal lipping and osteophytes in the lumbar vertebrae; middle-adult male from Korti T.31. Photograph by I. Kozieradzka-Ogunmakin.

tis (Mays 2007) was recorded in the spine of a young-adult male from Mansourkotti T.25. The individual's fourth lumbar vertebra showed an area of erosion to the antero-superior margin of the vertebral body resulting in the loss of a wedge-shaped portion of the body margin (**Figure 14**).

Degenerative joint disease was the second most frequently recorded pathology in the Late Meroitic assemblage (**Table 5**). In total, 10 of 16 (62.5%) individuals showed evidence of degenerative changes in the spine, including porosity and pitting, marginal osteophytes, widening and flattening of the joint surfaces (**Figure 15**) (Waldron 2009:24-45). The cervical and lumbar regions were predominantly affected. Degenerative changes were also observed in the major joints of the appendicular skeleton, including the glenohumeral and femoroacetabular joint, elbow and knee joint, as well as in the foot (predominantly the first ray). Eburnation was recorded only in the intertarsal and interphalangeal joints of the rays.

Other findings in the Late Meroitic skeletal assemblage included two cases of additional lumbar vertebra (L6) and its sacralization, recorded in a middle-adult male



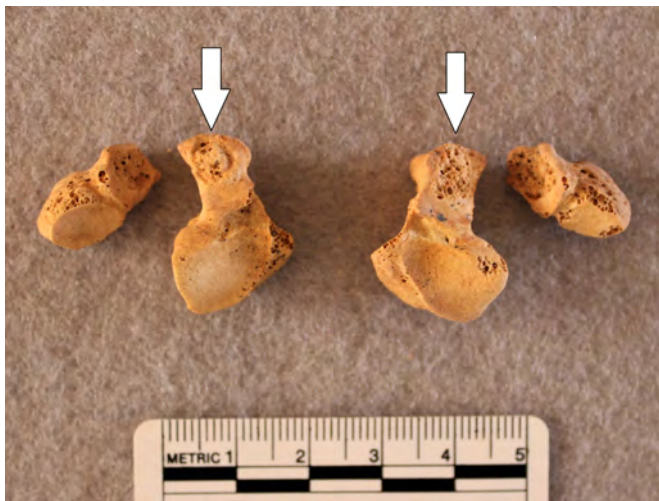


**Figure 16.** Unilateral sacralisation of additional lumbar vertebra (L6) in a middle-adult male from Mansourkotti T.35; note osteophytes in L2-6. Photograph by I. Kozieradzka-Ogunmakin.

from Mansourkotti T.35 (unilateral sacralisation; **Figure 16**) and a young female from Ousli T.42 (bilateral sacralisation). A case of unilateral congenital lunotriquetral coalition was recorded in a young-adult female from Ousli T.6 (**Figure 17**). It is the most common carpal coalition, a condition that affects 1% of the modern global



**Figure 17.** Congenital fusion of the right lunate and triquetral (Type 2 – fusion with a “notch” between the fused bones); young-adult female from Ousli East T.6. Photograph by I. Kozieradzka-Ogunmakin.



**Figure 18.** Bilateral congenital incomplete coalition resembling pseudoarthrosis (Type 1) of the pisiform and hamate; young-adult female from Ousli East T.6. Photograph by I. Kozieradzka-Ogunmakin.

population (Chew et al. 2012). Also recorded in the same individual was a bilateral incomplete fusion resembling pseudoarthrosis of the hamate and pisiform (**Figure 18**), being a Type 1 according to Minnaar's classification of carpal coalition (Devillers Minnaar 1952). The pisiform-hamate coalition is considered a rare anomaly that results from the metaplastic conversion of ligament into bone (Saylisoy et al. 2011). To date, around ten clinical cases have been reported (Inui et al. 2019) and no archaeological cases are known to the author.

Symphalangism of the foot digits was recorded in three individuals (Korti T.16B – M; Ousli East T.9 – F; Ousli East T.17 – M), affecting the intermediate and distal phalanges of the fifth ray. In total, 3 of 8 (37.5%) individuals with middle and distal lateral phalanges present in at least one foot showed evidence of this anomaly. A possible case of metastatic cancer was recorded in an older-adult female from Ousli T.13; this case will be published separately.

Like many other archaeological populations, the present skeletal assemblage was severely under-represented by sub-adults, partly due to looting and excavation bias—the cemeteries were only partially excavated with the focus being on the most endangered burials. Thanks to their near completeness and good preservation, the skeletal remains from the Late Meroitic cemeteries at Mansourkotti, Korti and Ousli East presented an opportunity for a detailed osteological examination and recording of pathological conditions and identification of rare anomalies. The findings present an insight into the health status and lifestyle of the past local population during the time of major agricultural, cultural, social, and political changes in the Meroitic kingdom. Dental enamel samples collected from the individuals have been used to investigate mobility and climate change at the fall of the Meroitic kingdom using stable isotope analysis (Kozieradzka-Ogunmakin & Sołtysiak submitted).

**Acknowledgments:** Research on human remains from Korti and Ousli East was conducted as part of the 'Environmental Changes and the Collapse of the Kingdom of Meroe, Sudan' project, funded from the European Union's Horizon 2020 research and innovation programme under the Marie Skłodowska-Curie grant agreement no. 665778, and the National Science Centre, Poland, under the POLONEZ grant agreement no. 2016/21/P/HS3/00893. Grateful thanks are extended to Dr Abdelrahman Ali Mohamed and Abdelhay Abdelsawi, National Corporation for Antiquities and Museums in Sudan, for facilitating access to skeletal remains from the Dam-Debba Archaeological Survey Project (DDASP), samples export permission, and their continued support. AMS dating was conducted by Poznań Radiocarbon Laboratory and Gliwice Radiocarbon Laboratory, Silesian University of Technology.

## References

- Abdelsawi A. (2019), *Dam-Debba Archaeological Survey Project (QSAP 14): Five seasons of archaeological activities*, Sudan & Nubia 23:95–100.
- AlQahtani S.J., Hector M.P., Liversidge H.M. (2010), *Brief communication: The London atlas of tooth development and eruption*, American Journal of Physical Anthropology 142:481–490.
- Bronk Ramsey C. (2009), *Bayesian analysis of radiocarbon dates*, Radiocarbon 51:337–360.
- Buckley S., Usai D., Jakob T., Radini A., Hardy K. (2014), *Dental calculus reveals unique insights into food items, cooking and plant processing in Prehistoric central Sudan*, PLoS ONE 9(7):e100808.
- Buikstra J.A., Ubelaker D.H. (eds.) (1994), *Standards for data collection from human skeletal remains*, Fayetteville: Arkansas Archaeological Survey.
- Chen E.M., Masih S., Chow K., Matcuk G., Patel D. (2012), *Periosteal reaction: Review of various patterns associated with specific pathology*, Contemporary Diagnostic Radiology 35:1–6.
- Chew F., Mulcahy H., Ha A.S. (2012), *Musculoskeletal imaging: A teaching file*, Philadelphia: Lippincott Williams & Wilkins.
- Colles A. (2006), *On the fracture of the carpal extremity of the radius*, *Edinburgh Medical Surgical Journal* 1814;10:181, Clinical Orthopaedics and Related Research 445:5–7.
- Devilliers Minnaar A.B. (1952), *Congenital fusion of the lunate and triquetral bones in the South African Bantu*, Journal of Bone and Joint Surgery (Br) 34(1):45–48.
- Dupras T.L., Wheeler S.M., Williams L., Sheldrick P. (2015), *Birth in Ancient Egypt: Timing, trauma, and triumph? Evidence from the Dakhleh Oasis* [in:] “Egyptian bioarchaeology: Humans, animals, and the environment”, S. Ikram, J. Kaiser, R. Walker (eds.), Leiden: Sidestone Press, pp. 53–66.
- Edelson J.G., Zuckerman J., HersHKovitz I. (1993), *Os acromiale: anatomy and surgical implications*, Journal of Bone and Joint Surgery 75(4):551–555.
- Edwards D. (2004), *The Nubian past. An archaeology of the Sudan*, London: Routledge.
- Ferraro M., Vieira A.R. (2010), *Explaining gender differences in caries: A multifactorial approach to a multifactorial disease*, International Journal of Dentistry 2010: e649643.
- Goodman A.H., Rose J.C. (1990), *Assessment of systemic physiological perturbations from dental enamel hypoplasias and associated histological structures*, Yearbook of Physical Anthropology 33:59–110.
- Guyomarc’h P., Campagna-Vaillancourt M., Kremer C., Sauvageau A. (2010), *Discrimination of falls and blows in blunt head trauma: A multi-criteria approach*, Jour-

- nal of Forensic Science 55(2):423–427.
- Halcrow S., Harris N., Beavan N., Buckley H. (2014), *First bioarchaeological evidence of probable scurvy in Southeast Asia: Multifactorial etiologies of vitamin C deficiency in a tropical environment*, International Journal of Paleopathology 5:63–71.
- Hassan Bakheit F. (2016), *Late Meroitic cemetery in Mansourkotti, Northern Sudan*, Nyame Akuma 86:80–86.
- Hassan Bakheit F. (2015), *QSAP Dam-Debba Archaeological Survey Project (DD SAP). Preliminary results of the second season*, Sudan & Nubia 19:149–160.
- Hill R.M.F., Robinson C.M., Keating J.F. (2001), *Fractures of the pubic rami*, Journal of Bone and Joint Surgery B 83(8):1141–1144.
- Hillson S. (2019), *Dental pathology* [in:] “Biological anthropology of the human skeleton”, 3<sup>rd</sup> ed., M.A. Katzenberg, A.L. Grauer (eds.), Oxford: Wiley Blackwell, pp. 295–334.
- Inui A., Mifune Y., Nishimoto H., Niikura T., Kuroda R. (2019), *A case of a painful coalition between pisiform and hamate*, Case Reports in Plastic Surgery and Hand Surgery 6(1):35–37.
- Judd M.A. (2012), *Gabati. A Meroitic, Post-Meroitic and Medieval cemetery in central Sudan, Volume 2, Physical Anthropology*, London: The Sudan Archaeological Research Society.
- Kozieradzka-Ogunmakin I., Sołtysiak A. (submitted), *Isotopic evidence of an environmental shift at the fall of the Kushite kingdom of Meroe, Sudan*, Antiquity.
- Machado M.J., Pérez-González A., Benito G. (1998), *Paleoenvironmental changes during the last 4000 yr in the Tigray, Northern Ethiopia*, Quaternary Research 49:312–321.
- Mays S. (2007), *Lysis at the anterior vertebral body margin: Evidence for brucellar spondylitis?*, International Journal of Osteoarchaeology 17:107–118.
- Merbs C.F. (1989), *Spondylolysis: Its nature and anthropological significance*, International Journal of Anthropology 4:163–169.
- Moczygomba C.K., Parmsothy P., Meikle S., Kourtis A.P., Barfield W.D., Kuklina E., Posner S.F., Whiteman M.K., Jamieson D.J. (2010), *Route of delivery and neonatal birth trauma*, American Journal of Obstetrics 361:1–6.
- Monjok E. (2008), *Clavicle fractures during birth*, American Family Physician 78:697.
- Moore J., Koon H.E.C. (2017), *Basilar portion porosity: A pathological lesion possibly associated with infantile scurvy*, International Journal of Paleopathology 18:92–97.
- Nikita E. (2017), *Osteoarchaeology: A guide to the macroscopic study of human skeletal remains*, Oxford: Academic Press.
- Ortner D.J., Ericksen M. (1997), *Bone changes on the human skull probably resulting from scurvy in infancy and childhood*, International Journal of Osteoarchaeology 7:212–220.

- Ortner D., Butler W., Cafarella J., Milligan L. (2001), *Evidence of probable scurvy in subadults from archaeological sites in North America*, *American Journal of Physical Anthropology* 114:343–351.
- Pecci M., Kreher J.B. (2008), *Clavicle fractures*, *American Family Physician* 77(1): 65–70.
- Reimer P.J., Austin W.E.N., Bard E., Bayliss A., Blackwell P.G., Bronk Ramsey C., Butzin M., Cheng H., Edwards R.L., Friedrich M., Grootes P.M., Guilderson T.P., Hajdas I., Heaton T.J., Hogg A.G., Hughen K.A., Kromer B., Manning S.W., Muscheler R., Palmer J.G., Pearson C., van der Plicht J., Reimer R.W., Richards, D.A., Scott, E.M., Southon J.R., Turney C.S.M., Wacker L., Adolphi F., Büntgen U., Capano M., Fahrni S.M., Fogtmann-Schult A., Friedrich R., Köhler P., Kudsk S., Miyake F., Olsen J., Reinig F., Sakamoto M., Sookdeo A., Talamo S. (2020), *The IntCal20 northern hemisphere radiocarbon age calibration curve (0–55 cal kBP)*, *Radiocarbon* 62(4):725–757.
- Sammarco V.J. (2000), *Os acromiale: Frequency, anatomy, and clinical implications*, *Journal of Bone and Joint Surgery (Am)* 82:394–400.
- Saylisoy S., Akcan E., Atlanoglu S., Calisir C., Inan U., Oztunali C. (2011), *Incomplete left-hand and complete right-hand pisiform and hamate coalition: Multidetector computed tomography findings*, *Japanese Journal of Radiology* 29(4):276–278.
- Waldron T. (2009), *Palaeopathology*, Cambridge: Cambridge University Press.
- Weston D.A. (2011), *Nonspecific infection in palaeopathology: Interpreting periosteal reactions* [in:] “A companion to paleopathology”, A.L. Grauer (ed.), Chichester: Blackwell Publishing, pp. 492–512.
- Williams M.A.J. (2009), *Late Pleistocene and Holocene environments in the Nile basin*, *Global and Planetary Change* 69(1):1–15.